

"Tips, Quips, and Pearls" is a special section in The Journal of Foot & Ankle Surgery which is devoted to the sharing of ideas to make the practice of foot and ankle surgery easier. We invite our readers to share ideas with us in the form of special tips regarding diagnostic or surgical procedures, new devices or modifications of devices for making a surgical procedure a little bit easier, or virtually any other "pearl" that the reader believes will assist the foot and ankle surgeon in providing better care. Please address your tips to: D. Scot Malay, DPM, MSCE, FACFAS, Editor, The Journal of Foot & Ankle Surgery, PO Box 590595, San Francisco, CA 94159-0595; E-mail: malays@uphs.upenn.edu

Frontal Plane–Guided Percutaneous Tendo Achilles' Lengthening

Alfonso A. Haro, III, DPM, FACFAS,¹ and Lawrence A. DiDomenico, DPM, FACFAS²

The authors review the historical evolution of the percutaneous tendo Achilles' lengthening (PTAL), pertinent anatomy, and advantages and disadvantages of the procedure, and present a technique for addressing gastrosoleus equinus, using the frontal plane rearfoot valgus or varus as the guiding factors when placing incisions for triple partial transection PTAL. The PTAL is being increasingly utilized to alleviate excessive plantar foot pressures to aid in treating chronic ulcers associated with diabetic, neuropathic, and post partial foot amputations, and is often considered the surgical treatment of choice for nonspastic gastrosoleus equinus (1).

Foot and ankle surgeons frequently lengthen the gastrosoleus complex via a tendo Achilles' lengthening as an adjunctive procedure to address ankle equinus secondary to congenital or acquired etiologies. Ancient civilizations used simple tenotomies and the PTAL to treat spastic equinus and talipes equino varus (1, 2). Delpech began performing the subcutaneous Achilles' tenotomy in 1816 to aid in the correction of clubfoot and was the first to publish the procedure in 1823 (1, 3, 4). Hibbs presented the first paper using the PTAL to correct equinus associated with pes plano valgus in 1914 (1, 5). Descriptions of the tendo Achilles'

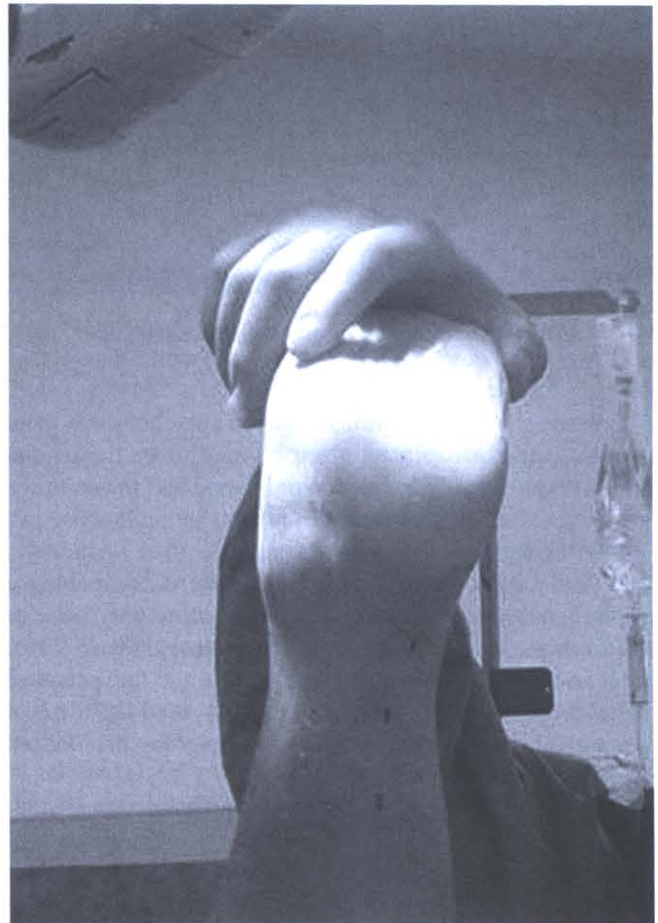


FIGURE 1 Calcaneal valgus incision planning.

Address correspondence to: Alfonso A. Haro, III, DPM, FACFAS, Foot and Ankle Center of North Carolina, 3 Regional Circle, Suite B, Pinehurst, NC 28374. E-mail: alfonsoaharorii@aol.com.

¹Fellow, Ankle and Foot Care Centers/Ohio College of Podiatric Medicine, Youngstown, OH.

²Forum Health/Western Reserve Care System, and Director, Reconstructive Rearfoot & Ankle Surgical Fellowship, Ankle and Foot Care Centers/Ohio College of Podiatric Medicine, Youngstown, OH.

Copyright © 2007 by the American College of Foot and Ankle Surgeons
1067-2516/07/4601-0010\$32.00/0

doi:10.1053/j.jfas.2006.10.006

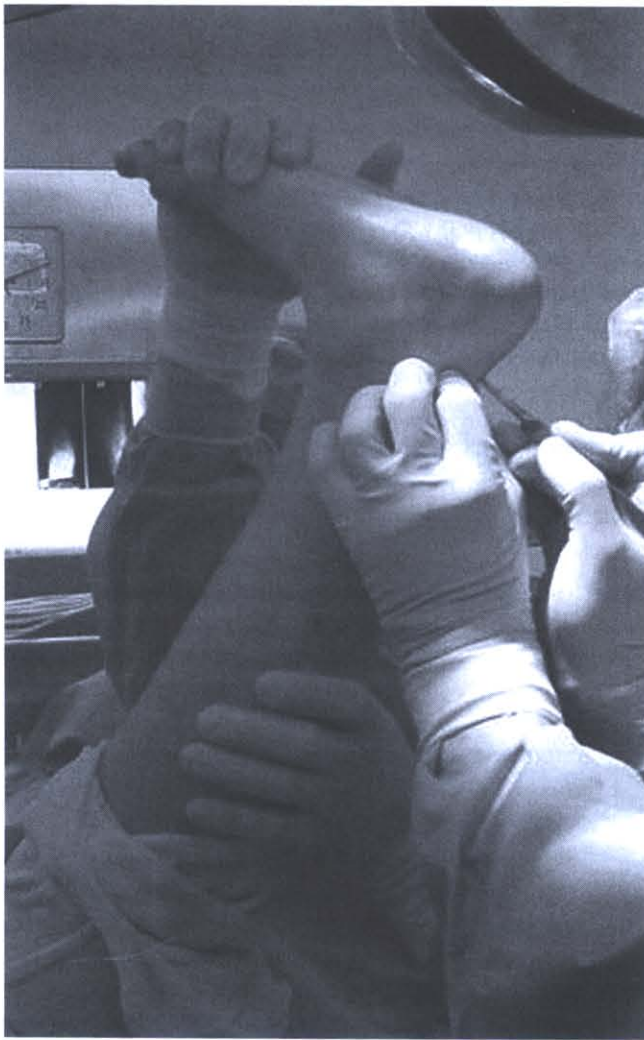

FIGURE 2 Calcaneal valgus distal lateral incision.

lengthening procedure utilizing various percutaneous techniques include: snap tenotomies; bi- and tri-partial tendon transactions, ranging from one third to one half to two thirds of the tendon; primary medial or lateral transactions; and frontal or sagittal plane transactions (1, 3, 6–13). In 1947, Hatt and Lamphier published Hoke's PTAL describing a triple hemisection technique, which is commonly used as the example by which a PTAL is performed (9). In 2005, Lee and Ko presented a paper evaluating the adequate distance between triple hemisections and used the rearfoot position as the determining factor when plotting the incision sites (7).

Relevant anatomy includes the origin of the gastrocnemius, soleus, and plantaris muscles; the gastrocnemius aponeurosis; the Achilles' and plantaris tendons, as well as their insertions on the calcaneus. The bipennate gastrocnemius muscle originates above the knee from the medial and lateral femoral condyles. The soleus muscle is flat and

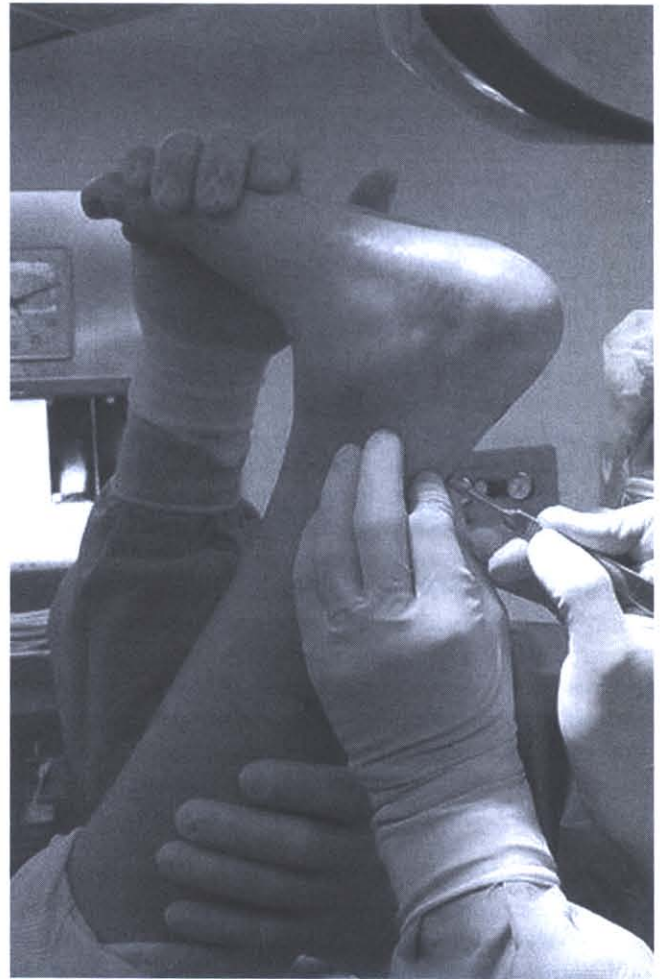


FIGURE 3 Calcaneal valgus central medial incision.

broad and originates below the knee from the posterior tibia and fibula. The medial head of the gastrocnemius extends more distally than the lateral head, and it converges to yield the anterior gastrocnemius aponeurosis fibers, which rotate from proximal medial to distal lateral. The gastrocnemius aponeurosis converges with the posterior aponeurosis of the soleus muscle to form the gastrosoleus aponeurosis, which continues distally in the same spiral rotation, forming the Achilles' tendon that inserts on the posterior central one third of the calcaneus. The gastrocnemius's contribution to the insertion of the Achilles' tendon is primarily superficial lateral and, to a lesser extent, deep lateral (3, 14). The soleus's contribution to the insertion of the Achilles' tendon on the calcaneus is primarily medial, equaling approximately two thirds of the deep surface and a small portion of the superficial surface (3, 14). Estimated measurements of the Achilles' tendon include: length of 15 cm, width of 20 mm, and thickness of 5 to 6 mm at the level of the ankle joint (3, 15–18). Van Gils et al examined 16 cadavers and reported the following results regarding the Achilles' ten-

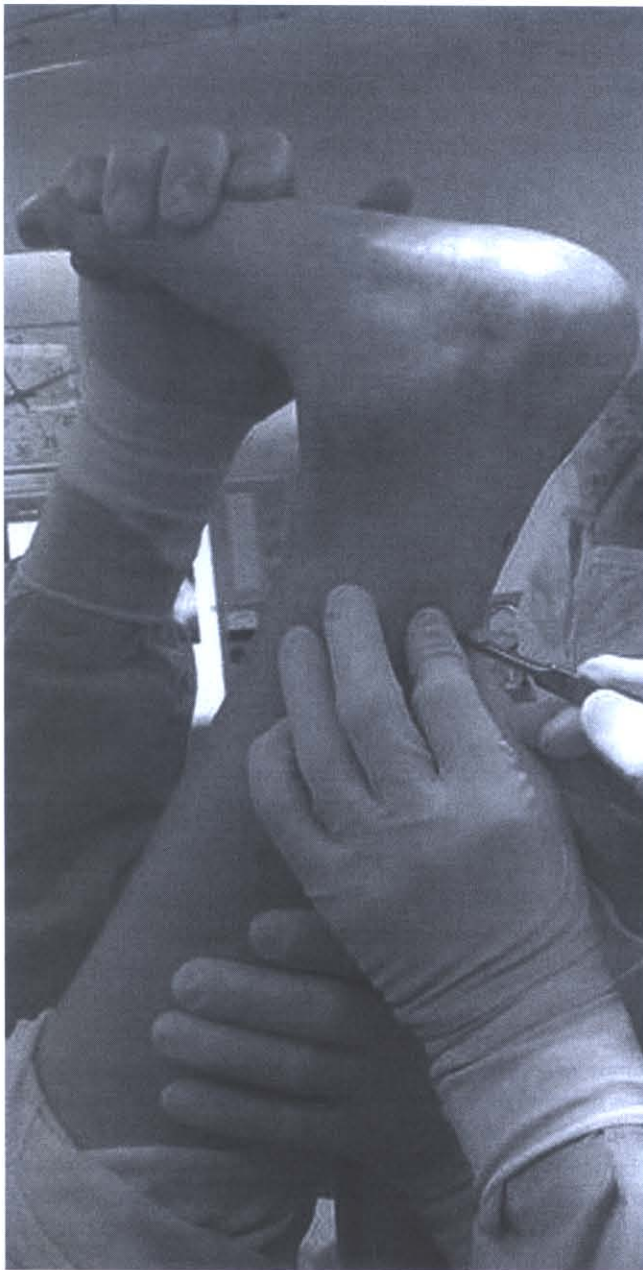

FIGURE 4 Calcaneal valgus proximal lateral incision.

don: degree of torsion ranged from 11° to 65°, with a mean of 37°; length ranged from 14.5 to 19.2 cm, with a mean of 16.8 cm; width at insertion ranged from 19 to 29.5 mm, with a mean of 24.3 mm; gastrocnemius portion of the posterior tendon at insertion ranged from 41% to 71%, with a mean of 61% of the Achilles' tendon fibers; the gastrocnemius portion of the Achilles' tendon revealed a mean angle of 8° of lateral deviation; twist of the tendon began 10.6 cm proximal to the calcaneal insertion; and torsion increased as the angle of malleolar position increased (3). Van Gils et al also noted that the Achilles' tendon torsion primarily

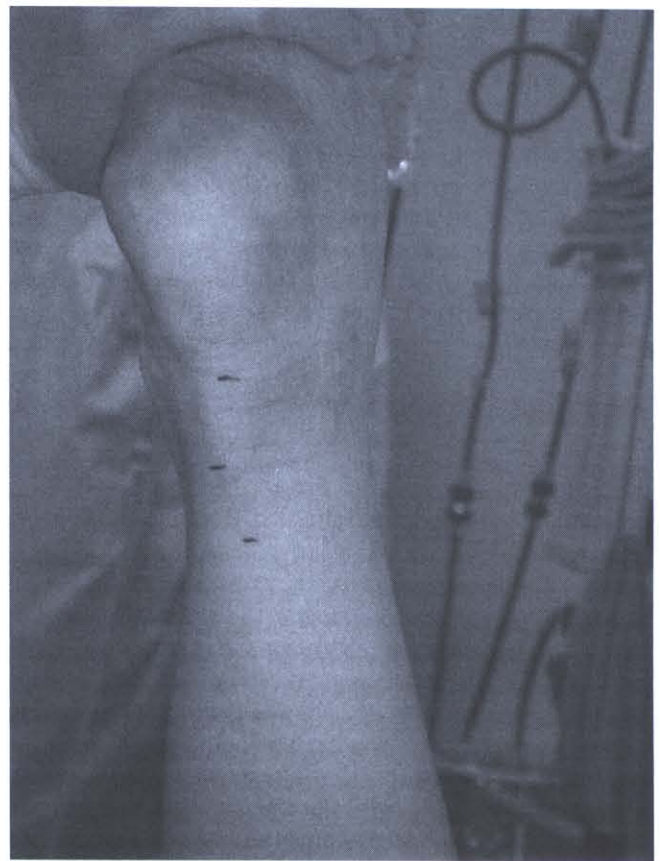

FIGURE 5 Calcaneal varus incision planning.

occurs in the distal two thirds of the tendon, rotates from medial to lateral, always exists but with high degrees of variability, and is usually much less than the 90° as described by White (3, 6). The plantaris muscle originates above the knee from the lateral femoral condyle, and the tendon extends distally, coursing medial to the Achilles tendon and inserting on the medial aspect of the posterior central one third of the calcaneus. The relationship of the Achilles' tendon to the calcaneus, gastrocnemius muscle, and paratenon as well as the location of the watershed area is important when considering the tendon's blood supply. The blood supply of the Achilles' tendon is primarily provided via the calcaneus distally, the gastrocnemius muscle proximally, and, to a lesser extent, the paratenon. The proximal and distal blood supply yields a central location of less vascularity, referred to as the watershed area, which is noted to be 4 to 6 cm proximal to the Achilles' tendon insertion on the calcaneus. Insult to the watershed area and paratenon should be avoided or minimized during lengthening of the Achilles' tendon. The course of the plantaris tendon, sural nerve, and saphenous vein is of importance to avoid iatrogenic injury and to ensure complete release of the plantaris tendon.

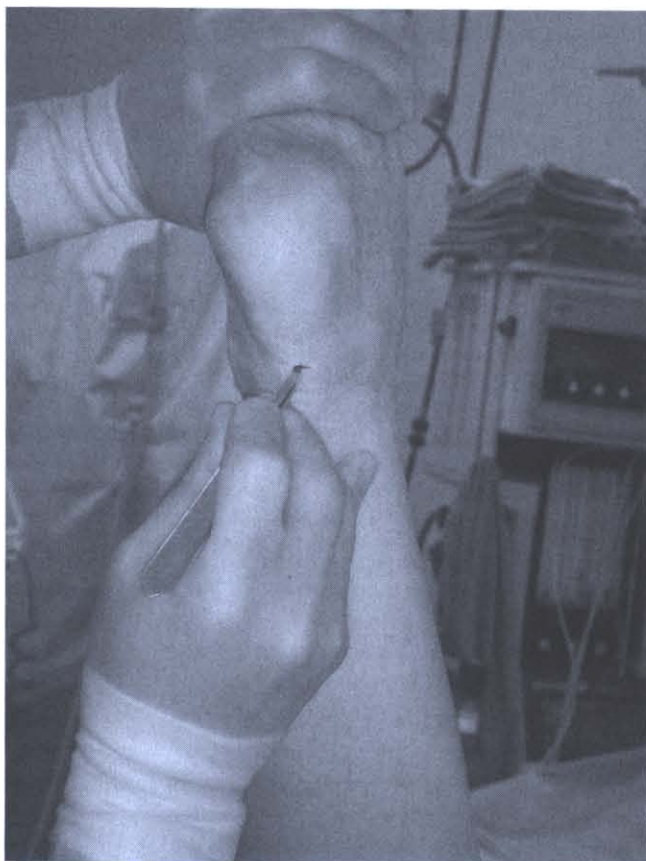

FIGURE 6 Calcaneal varus distal medial incision.

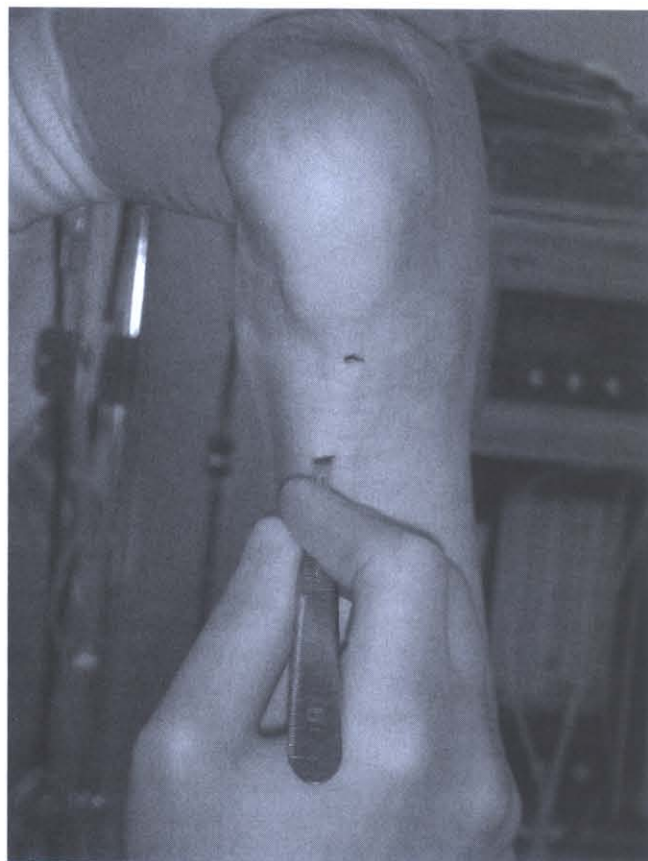

FIGURE 7 Calcaneal varus central lateral incision.

Surgical Technique

The patient is placed supine on the operative table and anesthesia is provided. The thigh tourniquet is applied but not inflated, and the foot and leg are prepped and draped above the knee. The foot is placed in a neutral subtalar joint position, the rearfoot to leg relationship is evaluated, and the calcaneus position is verified as being neutral, valgus, or varus. The foot is then supinated, maximally dorsiflexed, and elevated by the assistant, providing the surgeon direct visualization to the posterior leg and skin overlying the taut Achilles' tendon (Fig 1). The central one third of the posterior aspect of the calcaneus is identified as the insertion site of the Achilles' tendon, and 3 incision sites are mapped out from distal to proximal. If the calcaneus is in a neutral or valgus position, the incisions are planned in the following manner: the first is approximately 3 cm proximal to the insertion site and lateral, the second is approximately 6 cm proximal and medial, and the third is approximately 11 cm proximal and lateral. The specific location and distance between each partial transection minimize trauma to the paratenon and watershed area while allowing up to 3 cm of tendon sliding. Using the thumb and index finger of the nondominant hand, the surgeon palpates the medial and

lateral margins of the Achilles' tendon. A skin marker is used to make 3 longitudinal marks on the skin approximately 5 mm in length directly over the palpable Achilles' tendon. The distal lateral mark is placed so that it delineates the lateral one third from the medial two thirds of the Achilles' tendon. The central medial mark is placed so that it delineates the medial one third from the lateral two thirds of the Achilles' tendon. The proximal lateral mark is placed so that it delineates the lateral one third from the medial two thirds of the Achilles' tendon. A 15 blade is used to create a longitudinal stab incision through the skin and distal lateral one third of the Achilles' tendon. The blade is inserted perpendicular to the skin, cutting edge cephalic, and longitudinal to the Achilles' tendon (Fig 2). Once the blade is advanced (15 blade, approximately 15 mm) through the tendon, it is rotated 90° so that the cutting edge is orientated lateral and perpendicular to the longitudinal course of the Achilles' tendon. The scalpel handle and surgeon's hand are then slowly advanced anterior and medially so that the cutting edge of the blade advances laterally, transversely, and posteriorly, transecting the lateral one third of the Achilles' tendon. As the blade transects the tendon, the surgeon should appreciate a sensation of cutting through celery and stop the advancement of the cutting edge

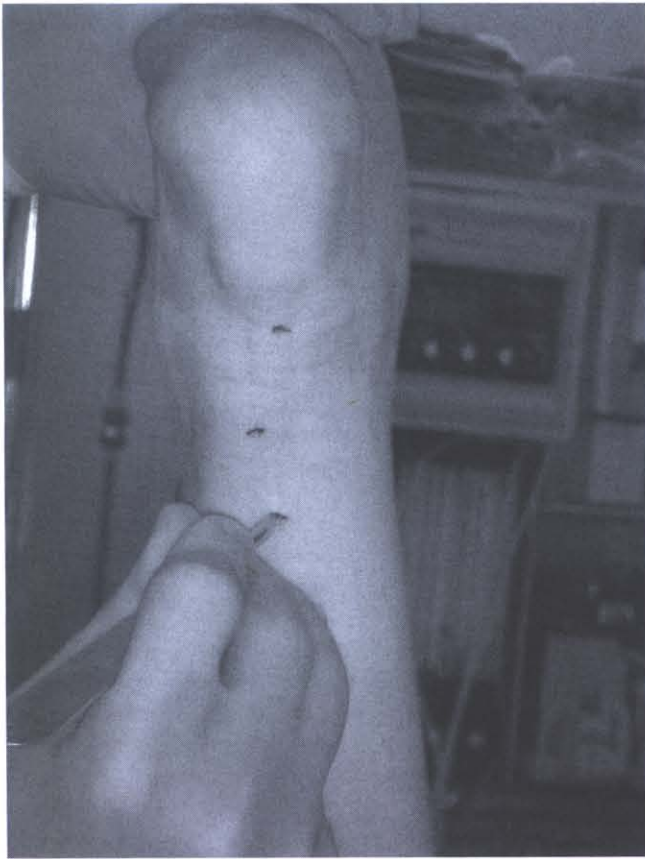


FIGURE 8 Calcaneal varus proximal medial incision.

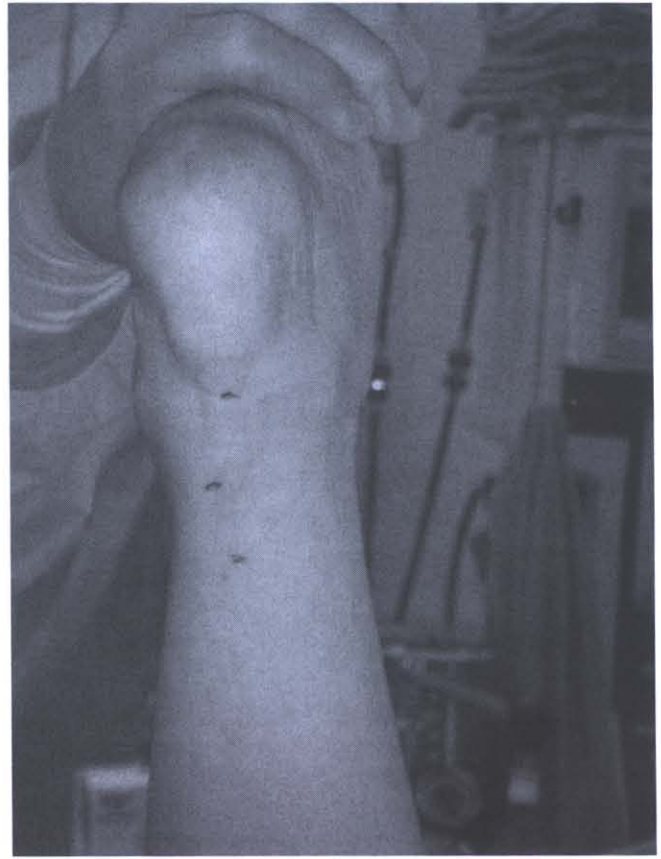


FIGURE 9 Calcaneal varus distal medial to central lateral to proximal medial PTAL.

of the blade once it exits the tendon shy of the surrounding deep tissue, sural nerve, and overlying skin. The scalpel and surgeon's hand are returned to the initial starting position and the blade is removed from the skin, oriented exactly as it was inserted, leaving only the original longitudinal incision in the skin and paratenon. Attention is then directed to the previously identified central medial one third of the Achilles' tendon (Fig 3). The medial one third of the Achilles' tendon is transversely transected using the same technique, with exception of the scalpel handle and surgeon's hand being slowly advanced anterior and laterally so that the cutting edge of the blade advances medially, transversally, and posteriorly, transecting the medial one third of the Achilles' tendon. The scalpel and surgeon's hand are then returned to the initial starting position and the blade is removed from the skin, oriented exactly as it was inserted. Attention is then directed to the previously marked proximal lateral one third of the Achilles' tendon, where the same technique is reproduced as described for the distal lateral one third of the Achilles' tendon transection (Fig 4).

If initial evaluation confirms rearfoot varus, then the previously described steps are performed with the exception of the placement of the incisions (Fig 5). In the presence of rearfoot varus, the distal incision is placed medial, facilitat-

ing transection of the medial one third of the tendon (Fig 6); the central incision is placed lateral, facilitating transection of the lateral one third of the tendon (Fig 7); and the proximal incision is placed medial, facilitating transection of the medial one third of the tendon (Fig 8). Despite the starting location, all 3 partial transections of the Achilles' tendon are through the lateral or medial one third of the tendon, therefore avoiding violation of the central one third of the tendon (Figs 9–11). If residual equinus exists, the same incision sites may be used to reintroduce the blade and transect additional tendon fibers. Up to one half of the tendon may require transecting at each location; however, the greater the amount of fibers transected, the greater the risk of an iatrogenic Achilles' tendon rupture.

The assistant and surgeon should appreciate a noticeable release of the Achilles' tendon and an increase in the available ankle dorsiflexion on completion of the 3-incision PTAL procedure. One should attempt to obtain a minimum of 90° of ankle dorsiflexion up to 10° to 15° past 90°, with the foot in a neutral subtalar joint position, midtarsal joint adducted, and the knee fully extended. The incisions are irrigated with normal saline solution, reapproximated, and coapted with 4-0 nonabsorbable simple sutures (Fig 12).

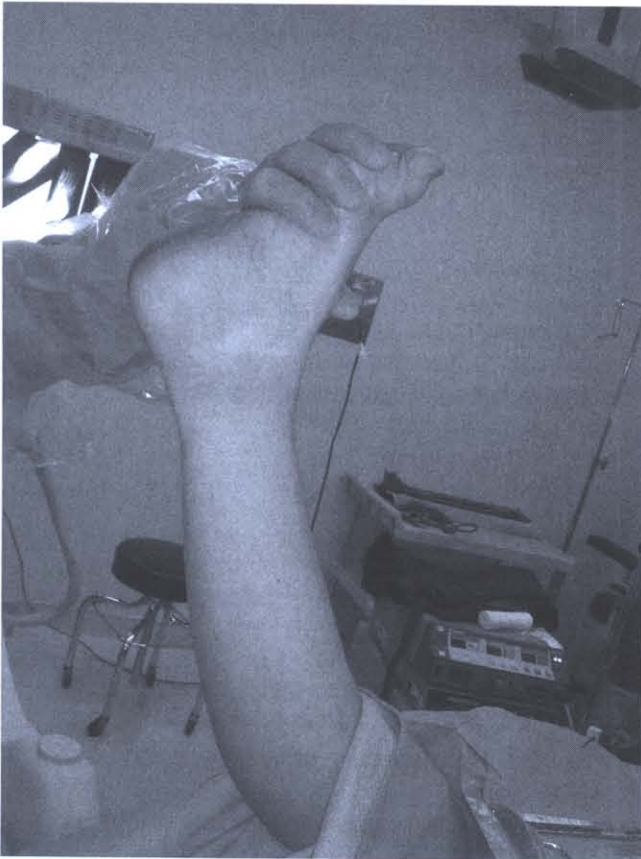

FIGURE 10 Prelateral distal medial to central lateral to proximal medial PTAL.

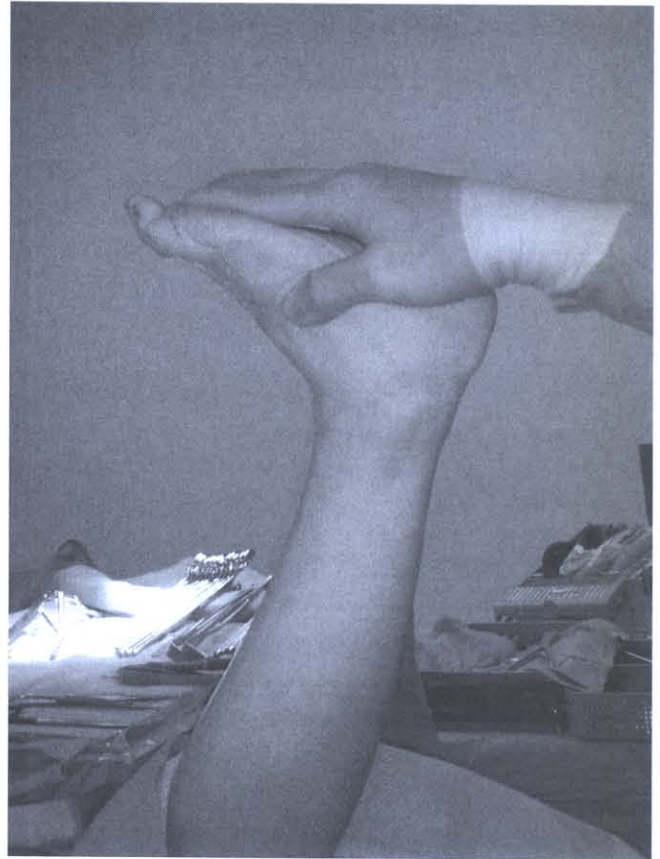


FIGURE 11 Postlateral distal medial to central lateral to proximal medial PTAL.

The incisions are covered with a non-adherent dressing, 4 × 4 gauze, and six inch gauze wrap; meanwhile, the foot is held in a neutral position and dorsiflexed so that 90° of ankle dorsiflexion is maintained while web roll and a below-the-knee posterior L and U splint is applied and covered with ace wraps. The patient remains nonweightbearing in a splint or cast for 3 to 4 weeks and is then transitioned to partial weightbearing in a protective cam boot for an additional 4 to 6 weeks. At 8 to 10 weeks postoperatively, the patient is transitioned to a walking or running shoe. Progressive increased weight-bearing activity is allowed as tolerated without pain, and a gradual step-up program with physical therapy is initiated.

Discussion

Advantages of the frontal plane-guided PTAL technique include: 1) release of the greatest amount of fibers of the Achilles' tendon is associated with the greatest amount of rearfoot frontal plane deformity (distal lateral to central medial to proximal lateral for calcaneal valgus and distal medial to central lateral to proximal medial for calcaneal varus); 2) transections of the Achilles' tendon are performed

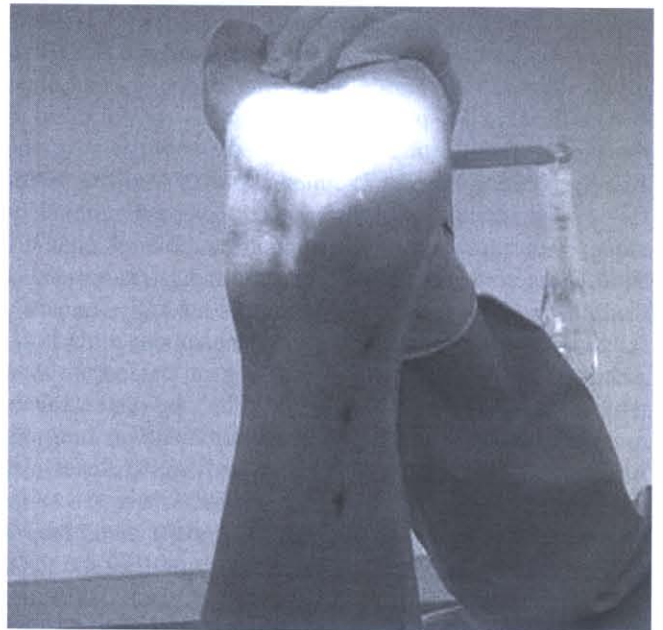

FIGURE 12 Calcaneal valgus distal lateral to central medial to proximal lateral PTAL.

at the periphery of the watershed area; 3) they may allow up to 3 cm of Achilles' tendon slide; 4) they minimize violation of the central one third of the tendon; 5) the distal lateral to central medial to proximal lateral release is consistent with the proximal medial to distal lateral angle of insertion of the gastrocnemius fibers of the Achilles' tendon; 6) they avoid the posterior medial neurovascular bundle; and 7) they allow greatest latitude for increasing the distance between the 3 stab incisions because the lateral head of the gastrocnemius muscle ends more proximally than the medial head. Additional advantages as presented by Lee and Ko include: short operative time, negligible scarring, immediate weight-bearing after surgery, short immobilization time, and little or no chance of developing calcaneal deformity (7). Advantages of the Hoke triple hemisection PTAL reported by Nishimoto et al include: it is a rapid procedure that may be performed under local anesthesia, and it has a low recurrence rate and minimal wound complications (19).

Disadvantages of the PTAL include: Achilles' tendon rupture due to 13% incidence of unintentional complete tenotomy (20); intraoperative (over sliding) during forced dorsiflexion; insufficient postoperative immobilization; lack of protected weightbearing or secondary to spastic gastrosoleus muscle contraction; imprecise lengthening such as overcorrection (over sliding); resulting in weakness of the triceps sure muscle complex; a 2% to 10% incidence of calcaneal gait (19); plantar heel ulceration; decreased stride length and velocity; decreased push-off strength; knee and ankle instability; and crouched gait in children with spastic conditions, or undercorrection, resulting in continued equinus and recurrence of equinus in spastic cases and in the presence of weak dorsiflexors; sural neuritis, nerve entrapment or neuroma; hematoma; infection; adhesions; and prolonged postoperative casting, resulting in disuse atrophy or cast disease (1, 7, 19–30).

To date, the lead author has performed 52 frontal plane-guided PTAL procedures over a 6-year period with no reported incidents of calcaneal gait or complete Achilles' tendon rupture. One case of transient sural neuritis was encountered, which is similar to results reported by Piriou et al who cited 1 case of pericalcaneal neuropathy as the only complication after 80 PTALs (31, 32).

References

- Downey MS. Ankle equinus. In *Comprehensive Textbook of Foot Surgery*, ed 2, vol 1, pp 687–730, edited by ED McGlamry, AS Banks, MS Downey, Williams & Wilkins, Baltimore, 1992.
- Rang M. The foot. In *The Story of Orthopaedics*, pp 93–104, edited by M Rang, W.B. Saunders, Philadelphia, 2000.
- van Gils CC, Steed RH, Page JC. Torsion of the human Achilles tendon. *J Foot Ankle Surg* 35:41–48, 1996.
- Delpach JM. Tenotomie du tendon d'Achille. *Chirurg Clin de Montpellier* 147–231, 1823.
- Stromeyer GF. Beitrage zur operativen Orthopadik oder Erfahrungen uber die subcutane Durchschneidung verkurzter Muskeln und deren Sehnen. Hanover, Helwing, 1838.
- White JW. Torsion of the Achilles tendon: its surgical significance. *Arch Surg* 46:784–787, 1943.
- Lee W-C, Ko H-S. Achilles tendon lengthening by triple hemisection in adult. *Foot Ankle Int* 26:1017–1020, 2005.
- Graham HK, Fixsen JA. Lengthening of the calcaneal tendon in spastic hemiplegia by the White slide technique. A long-term review. *J Bone Joint Surg* 70:472–475, 1988.
- Hatt RN, Lamphier TA. Triple hemisection: a simplified procedure for lengthening the Achilles tendon. *N Engl J Med* 236:166–169, 1947.
- Frost HM. Subcutaneous tendo Achilles lengthening. *Am J Orthop* 5:256–257, 1963.
- Hall JE, Salter RB, Bhalla SK. Congenital short tendo calcaneus. *J Bone Joint Surg* 49:695–697, 1967.
- Sgarlato TE. *A Compendium of Podiatric Biomechanics*. California College of Podiatric Medicine, San Francisco, 1971.
- Hansen ST. Surgical technique II: Percutaneous Achilles tendon lengthening. In *Functional Reconstruction of the Foot and Ankle*, pp 418–421, edited by ST Hansen, Jr, Lippincott Williams & Wilkins, Baltimore, 2000.
- Cummins EJ, Anson BJ, Car BW, Wright RR. The structure of the calcaneal tendon (of Achilles) in relation to orthopaedic surgery with additional observation on the plantaris muscle. *Surg Gyn Obstet* 83: 107–116, 1946.
- Feehery RV Jr. Surgery of the Achilles tendon and posterior muscle group. *Clin Podiatr Med Surg* 9:781–811, 1992.
- Williams PL, Warwick R, Dyson M, Bannister LH. Myology. In *Gray's Anatomy*, ed 37, pp 648, Churchill Livingstone, Edinburgh, 1989.
- Inman VT. Applications to orthopaedics. In *The Joints of the Ankle*, pp 75–80. Williams & Wilkins, Baltimore, 1976.
- Sarrafan SK. Myology. In *Anatomy of the Foot and Ankle*, ed 2, pp 279–281, JB Lippincott, Philadelphia, 1993.
- Nishimoto GS, Attinger CE, Cooper PS. Lengthening the Achilles tendon for the treatment of diabetic plantar forefoot ulceration. *Surg Clin North Am* 83:707–726, 2003.
- Berg EE. Percutaneous Achilles tendon lengthening complicated by inadvertent tenotomy. *J Pediatr Orthop* 12:341–343, 1992.
- Banks HH. The management of spastic deformities of the foot and ankle. *Clin Orthop* 122:70–76, 1977.
- McCarroll HR, Schwartzmann JR. Spastic paralysis and allied disorders. *J Bone Joint Surg* 25:745–746, 1943.
- Segal LS, Thomsa SES, Mazur JM, Mauterer M. Calcaneal gait in spastic diplegia after heel cord lengthening: a study with gait analysis. *J Pediatr Orthop* 9:697–701, 1989.
- Banks HH, Green WT. The correction of equinus deformity in cerebral palsy. *J Bone Joint Surg* 40:1395–1379, 1958.
- Etnyre B, Chambers CS, Scarborough NH, Cain TE. Preoperative and postoperative assessment of surgical intervention for equinus gait in children with cerebral palsy. *J Pediatr Orthop* 13:24–31, 1993.
- Garbarino JL, Clancy M. A geometric method of calculating tendo Achillis lengthening. *J Pediatr Orthop* 5:573–576, 1985.
- Mooney V, Perry J, Nickel VL. Surgical and nonsurgical orthopaedic care of stroke. *J Bone Joint Surg* 49:989–1000, 1967.
- Sharrard WJW, Bernstein S. Equinus deformity in cerebral palsy. A comparison between elongation of the tendocalcaneus and gastrocnemius recession. *J Bone Joint Surg [Br]* 54:272–276, 1972.
- Yamamoto H, Okumura S, Morita S, Obata K, Furuya K. Surgical correction of foot deformities after stroke. *Clin Orthop* 282:213–218, 1992.
- Blasier RD, White R. Duration of immobilization after percutaneous siding heel-cord lengthening. *J Pediatr Orthop* 18:299–303, 1998.
- Willrich A, Angirasa AK, Sage RA. Percutaneous tendo Achillis lengthening to promote healing of diabetic plantar foot ulceration. *J Am Podiatr Med Assoc* 95:281–284, 2005.
- Piriou P, Tremoulet J, Garreau De Loubresse C, Judet T. Subcutaneous tenotomy of Achilles tendon in adults for ankle stiffness: a review of 80 cases. *Rev Chir Orthop Reparatrice Appar Mot* 86:38–45, 2000.