



ELSEVIER  
SAUNDERS

Clin Podiatr Med Surg  
23 (2006) 611–620

---

---

CLINICS IN  
PODIATRIC  
MEDICINE AND  
SURGERY

---

---

## Anterior Tarsal Tunnel Syndrome

Lawrence A. DiDomenico, DPM<sup>a,\*</sup>,  
Eric B. Masternick, DPM<sup>b</sup>

<sup>a</sup>*Ohio College of Podiatric Medicine, Department of Surgery,*

*Northside Medical Center, 500 Gypsy Lane, Youngstown, OH 44505, USA*

<sup>b</sup>*Beeghly Medical Park, Suite 104, 6505 Market Street, Youngstown, OH 44512, USA*

Several nerve compression syndromes have been described in the foot and ankle literature. The most frequently reported syndrome is the posterior tarsal tunnel syndrome, which is compression of the posterior tibial nerve.

Entrapment neuropathy of the deep peroneal nerve, also recognized as the anterior tibial nerve, typically occurs at the anterior ankle and dorsal foot. It provides sensory innervation of the skin between the first and second digit of the dorsal aspect of the foot [1]. Compression of the nerve, which anatomically is inferior to the extensor retinaculum, is commonly referred to as anterior tarsal tunnel syndrome. Although rare, this syndrome remains poorly diagnosed among clinical problems. Kopell and Thompson [2] first described deep peroneal nerve entrapment in 1963. In 1968, Marinacci [3,4] named the entity anterior tarsal tunnel syndrome and established the electrodiagnostic technique to assist in the diagnosis. The deep peroneal is the main branch of the common peroneal nerve. The common peroneal nerve passes the peroneal tunnel at the fibular neck, and then divides into the superficial, deep, and recurrent peroneal nerves. The deep peroneal nerve runs into the anterior compartment of the lower extremity between the anterior tibial, extensor hallucis longus muscles, and tendons. The deep peroneal nerve innervates the anterior tibial, extensor digitorum longus, extensor hallucis longus, and peroneus tertius muscles. At the ankle joint, it travels under the inferior extensor retinaculum and divides into two terminal branches: the lateral branch which innervates the extensor digitorum brevis muscle, and the medial cutaneous branch which is responsible for sensation between the first and second toes [5].

Anterior tarsal tunnel syndrome is frequently characterized by pain, weakness, and sensory changes of the foot and ankle. Chronic biomechanical mal-alignment, acute trauma, a direct blow, a soft tissue mass, bony

---

\* Corresponding author.

E-mail address: LD5353@AOL.com (L.A. DiDomenico).

exostosis, and tight shoe gear are common etiological factors that lead to anterior tarsal tunnel syndrome. Severe and chronic ankle sprains can cause unwarranted traction on the deep peroneal nerve which leads to symptoms consistent with anterior tarsal tunnel syndrome. Entrapment of the proximal portion of the deep peroneal nerve can lead to atrophy and weaken the anterior musculature. Entrapment of the distal portion of the deep peroneal nerve can produce first interspace sensory deficit and paresthesia. According to the literature, the most common cause of this compression is repetitive compressive trauma from tight shoe straps or high heel shoes (Figs. 1 and 2) [5]. Anterior tarsal tunnel syndrome has been reported with association of edematous lower extremities. Abdul-Latif and colleagues [6] reported a case of anterior tarsal tunnel syndrome secondary to edema in the post partum period. The diagnosis of anterior tarsal tunnel syndrome is made based on comprehensive knowledge of the anatomy linked with the appropriate history and physical examination findings. Treatment varies from non-operative care to surgical release of the nerve and decompression [7].

### Anatomy

The deep peroneal nerve arises as a branch of the common peroneal nerve which courses around the neck of the fibula. The deep peroneal nerve enters the anterior compartment of the leg after it passes deep to the peroneus longus muscle and then flows obliquely forward beneath the extensor digitorum muscle. It then travels distally along the anterior surface of the interosseous membrane. In the upper one-third of the leg, the deep peroneal nerve is located between the extensor digitorum longus and the anterior tibialis muscles, and passes inferior to the extensor hallucis longus tendon in the lower one-third of the leg. The nerve is lateral to the anterior tibial artery and between the extensor hallucis longus and the extensor digitorum longus tendons, just proximal to the ankle joint. It then commonly divides into medial and lateral terminal branches about 1.3 cm above the ankle joint [8,9].

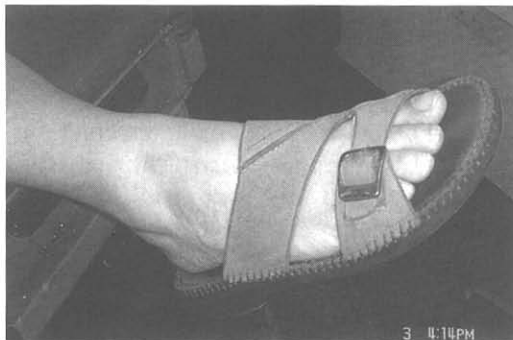

Fig. 1. A strap from a sandal can cause compression over the deep peroneal nerve.

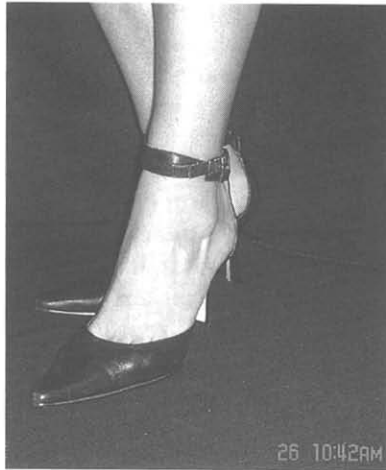

Fig. 2. A strap from a dress shoe can cause compression to the anterior ankle.

The medial branch travels to the first intermetatarsal space along the course of the dorsalis pedis artery which is located between the extensor hallucis longus tendon and the medial border of the extensor hallucis brevis muscle, where it pierces the deep fascia at the first webspace. At this point, it divides into two cutaneous nerves, which supply the medial aspect of the hallux and the lateral aspect of the second digit [8,9].

The lateral branch becomes enlarged just inferior to the extensor digitorum brevis muscle to supply a motor branch to the muscle and then gives off terminal branches to supply sensation to the second, third, and fourth metatarsophalangeal joints [8,9]. An accessory motor branch from the superficial peroneal nerve has been found to innervate the extensor digitorum brevis in 19% to 28% of subjects [10–13].

As the nerves and tendons pass along the ankle, they pass at almost a 90° angle; to prevent bowstringing they are held in place by retinacula. The superior extensor retinaculum is poorly definable and extends from the distal aspect of the fibula to the anterior tibial crest and medial malleolus. The inferior extensor retinaculum has a Y-shaped configuration, which originates from the sinus tarsi and tarsal canal laterally and then inserts into the medial malleolus proximally and the medial cuneiform and navicular distally [8,9].

### Clinical findings

Anterior tarsal tunnel syndrome most commonly presents with altered sensations such as hyperesthesia, hypesthesia in the dorsal first web space, paresthesia which radiates to the first web space, pain upon palpation of the deep peroneal nerve in the entrapped area, pain in the dorsum of the foot, loss of ability to hyperextend the digits and hallux, and a vague burning sensation in the distribution of the deep peroneal nerve [9,14]. Wasting

of the extensor hallucis brevis and extensor digitorum brevis muscles may be present. Two-point discrimination in the numb region may also be reduced with entrapment [1]. Tenderness to pressure along the deep peroneal nerve will be present either beneath the inferior extensor retinaculum, or distally at the apex of the first and second web spaces at the metatarso-cuneiform joints.

Pain associated with anterior tarsal tunnel syndrome usually worsens with activity and may reside with rest. Nighttime pain is also common because the foot is held in plantarflexion which causes the deep peroneal nerve to be at its stretched position [9,15]. Schon and coworkers [16] studied anterior tarsal tunnel syndrome in athletes and found that repetitive dorsal trauma, such as in soccer players, will cause similar symptoms. Repetitive trauma was also caused by bars used for sit-ups, and keys placed beneath the tongue of a running shoe (Fig. 3)[16].

As with any entrapment neuropathy, sensory abnormalities appear in the cutaneous distribution of the deep peroneal nerve. A Tinel's sign is elicited by percussion at the extensor hallucis brevis muscle. The patient's symptoms may be recreated by plantarflexion and inversion of the foot [9,14]. Confirmatory electrodiagnostic testing is recommended. In 28% of the patients there is the possibility of an accessory deep peroneal nerve which branches off of the superficial peroneal nerve [15].

### Differential diagnosis

When a patient presents with anterior foot pain, along with anterior tarsal tunnel syndrome, the differential diagnosis may include lumbosacral nerve root impingement, peripheral neuropathy, medial tarsal tunnel syndrome, Morton's neuroma, superficial nerve entrapment, gout, peripheral vascular disease, bony ankle impingement, and ankle sprain or fracture [15].

It is very important to distinguish between an entrapment of the superficial peroneal nerve and the deep peroneal nerve. The superficial peroneal

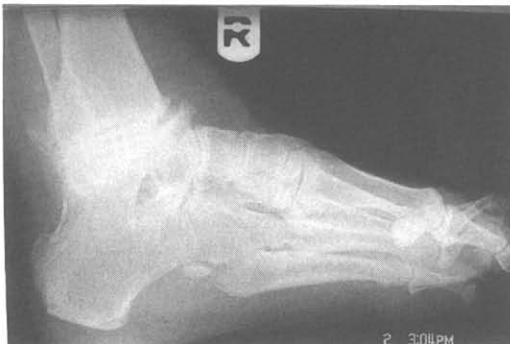

Fig. 3. Radiograph shows tibial talar exostosis, which causes compression and anterior tarsal tunnel syndrome.

nerve innervates the dorsum of the foot cutaneously, and percussion of the intermediate dorsal cutaneous branch will elicit paresthesia, pain, and a Tinel's sign. Compression of the superficial peroneal nerve will not result in muscle atrophy as would compression of the deep peroneal nerve [14].

Compression of the common peroneal nerve proximally at the level of the fibular neck must also be considered in the differential diagnosis of anterior tarsal tunnel syndrome. Compression of this nerve would result in weakness of the peroneals, anterior tibial, and extensor digitorum longus muscles. Even more proximal would be an L5 to S2 radiculopathy, which would produce more sensory impairment in a dermatomal pattern, and loss of Achilles tendon deep reflex [14,15,17].

Electromyographic and nerve conduction studies can determine if there is more proximal nerve involvement, such as lumbar radiculopathy, or if a polyneuropathy is present. The point of stimulation is proximal to where the entrapment is suspected and a delayed motor latency  $>5$  ms compared with the contralateral side, represents entrapment of the motor branch [18]. These results should be taken with caution and correlated with clinical findings because chronic or acute denervation of the extensor digitorum brevis is common in many other peripheral nerve diseases and also in some normal subjects.

## **Etiology**

Anterior tarsal tunnel syndrome is caused by a compression of the deep peroneal nerve either by the extensor hallucis longus tendon or the inferior extensor retinaculum. The nerve lies in an unprotected area of the foot and ankle and could also be compressed by the talar head as the nerve passes over the talonavicular joint area (Fig. 4) [1].

Anything that can cause abnormal compression of the deep peroneal nerve can be a cause of the syndrome including fracture, subluxations, soft tissue masses, and wearing high-laced boots. The deep peroneal nerve is placed under maximal stretch while the foot is in plantarflexion and the digits are extended: the position of the foot in high-heeled shoes worn by women [18]. This maximal stretch would also support the clinical findings that anterior tarsal tunnel syndrome is worse at night in some patients because of the position of the foot during sleep.

A biomechanical etiology of anterior tarsal tunnel syndrome described in the literature is a result of a rigid forefoot valgus deformity associated with a plantarflexed first ray, which is compensated for by subtalar supination and midtarsal joint inversion [19].

## **Treatment**

To treat anterior tarsal tunnel syndrome, conservative measures should be attempted first. Non-surgical treatment consists of removing external pressures that cause compression or traction on the deep peroneal nerve.

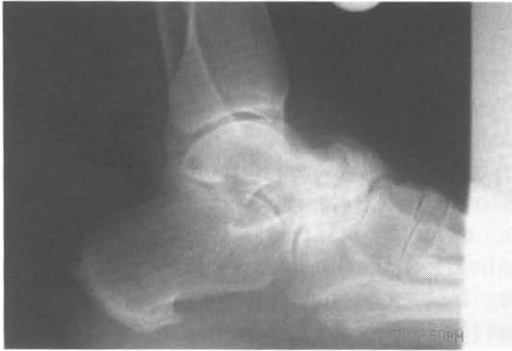

Fig. 4. Radiograph shows talar navicular exostosis, which causes compression to the deep peroneal nerve.

Initial non-operative treatment consists of patient education, pharmaceutical agents, local injections, physical therapy, and patient lifestyle modifications such as shoe wear and activity. Orthotics or accommodative shoes can help decrease the pressure over the nerve [20]. Different shoe gear, alternative lacing techniques, or appropriate padded areas may also accommodate the nerve. Patients who have recurrent ankle sprains and loss of proprioception might benefit from physical therapy to strengthen the peroneal muscles and improve ankle joint proprioception. Anticonvulsant or tricyclic antidepressant medications can diminish the neuritis and can be used in conjunction with pressure relieving treatment.

Conservative management of anterior tarsal tunnel syndrome has been successful. Abdul-Latiff and colleagues [6] reported a case in which post partum edematous lower extremities caused anterior tarsal tunnel syndrome and the patient responded well to leg elevation and diclofenac. Gessini and coworkers [21] reported on four cases of anterior tarsal tunnel syndrome: three patients responded to local steroid injection; the fourth patient responded to shoe gear modification. Non-steroidal anti-inflammatory medication and local infiltration of steroids at the site of entrapment are common traditional modalities used. When acute trauma is related to the deep peroneal nerve, immobilization is required. When neuropathy is associated with localized chronic edema, treatment of the primary condition may be effective.

If non-surgical efforts fail to relieve the symptoms, nerve decompression should be performed. The patient is placed in the supine position and receives either general or spinal anesthesia. The extremity is prepped in the usual sterile fashion and a mid-thigh tourniquet is used for hemostasis. A longitudinal or lazy S-shaped incision is made along the proximal ankle and extends to the base of the first and second tarsal-metatarsal joints. The incision is deepened between the extensor digitorum longus and extensor hallucis longus tendons. The nerve proximal to the cruciate crural

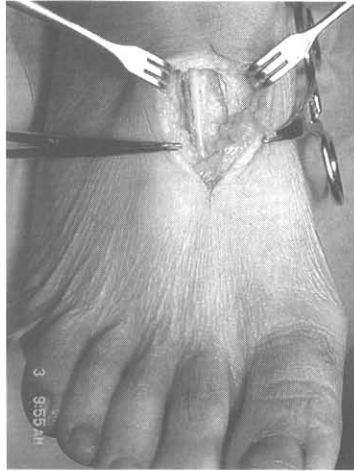

Fig. 5. An intra-operative view of the deep peroneal nerve after resection of the extensor hallucis brevis tendon.

ligament should be visible, and care should be taken to recognize the intermediate (Lemont's) and medial dorsal cutaneous nerves superficially [22]. The superiomedial and inferiomedial limbs of the inferior extensor retinaculum are divided. The deep peroneal nerve and the anterior tibial artery are identified. The deep peroneal nerve along with the lateral and medial branches is neurolysed. An exploration for osteophytes, scar tissue, lesions and masses is performed and removed if located. The portion of the extensor hallucis brevis tendon that crosses the deep peroneal nerve is bovied and resected (Fig 5). Using microsurgical instruments and technique, the epineurium is opened. If there is intraneural fibrosis present, an internal

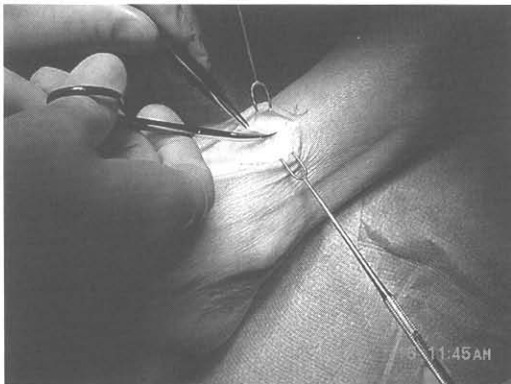


Fig. 6. An intra-operative view that shows decompression of a more proximal entrapment site.

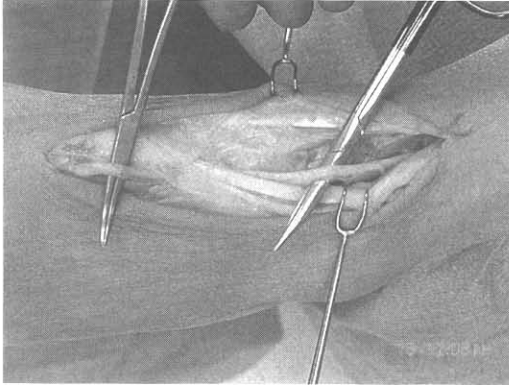


Fig. 7. An intra-operative view of the deep peroneal nerve after decompression proximal and distal. Note the extensor hallucis longus crossing over the nerve.

neurolysis is performed. The incision is closed with interrupted intradermal absorbable sutures and the skin is closed with staples.

For patients who have only a distal entrapment, an incision is made between the bases of the first and second metatarsals and extends proximal approximately 4 cm (Fig. 6). The incision is deepened into the subcutaneous tissues and the adjacent branches of the superficial peroneal nerve are acknowledged. The fascia is incised and the extensor hallucis brevis tendon is found crossing over the nerve. The tendon is bovid and a portion of the tendon is resected (over the nerve) and retracted. At this point the deep fascia is identified which causes pressure on the underlying nerve. The bony structures must be examined for osteophytes and, if any are present, resected. A release of the deep fascia proximally is performed and an internal neurolysis of the deep peroneal nerve is performed using microsurgical instruments and technique as indicated (Fig. 7). The incision is closed with interrupted intradermal absorbable sutures and the skin is closed with staples.

Postoperatively, the patient is injected with 10 mL of 0.5% marcaine along the incision. Adaptic, gauze, kerlex, and ace bandage are used from the metatarsal heads to the tibial tubercle for dressings. Early non-weight-bearing, range-of-motion exercises are encouraged. Patients should not bear weight for 2 weeks. The sutures are removed at 2 weeks and physical therapy is initiated.

## Summary

Symptoms of anterior tarsal tunnel syndrome include a shock-like pain to the dorsal aspect of the foot, sensory loss, paresthesia in the first interspace, and possible atrophy of the extensor digitorum brevis muscle [23]. The cause of the syndrome is compression of the deep peroneal nerve in the anterior



tarsal tunnel. There is very minimal soft tissue coverage at this anatomic site which leaves this area relatively unprotected. The site of entrapment can be at the superior edge of the inferior extensor retinaculum, over bony prominences of the dorsal medial tarsal bones, or under the extensor hallucis brevis tendon. Typical complaints heard from patients consist of vague neuritic aching pain of the foot and ankle. Numbness may or may not be present in the first web space. Atrophy of the extensor digitorum brevis muscle may be present if the nerve entrapment is proximal and involves the deep peroneal nerve motor branch. The nerve entrapment can be caused from external or internal compression. External compression is typically caused from contusion of the foot and ankle, tight boots, shoes, laces, or any pressure along the nerve. Bony lesions, soft tissue masses, scar tissue, or trauma that has initiated traction injuries to the local nerve can cause internal compression. The differential diagnosis of these indistinguishable symptoms is immense. The diagnosis is based on patient history and physical examination. Tinel's percussion sign is typically present at the site of the nerve entrapment. Injection therapy with a local anesthetic at the site of entrapment or proximal can help the physician make a diagnosis. Neurosensory testing, nerve conduction studies, and electromyograms can be used to assess for nerve disorders or a more proximal nerve involvement. Nerve conduction studies in the lower extremity have a relatively high error rate; therefore, a negative study does not eliminate the diagnosis of nerve dysfunction.

There are non-surgical and surgical treatment options. Initially, non-operative measures should be attempted to reduce or remove the external compression along the anterior aspect of the foot and ankle. Other non-surgical options are shoe modifications, and cortisone injections with or without local anesthetics. Physical therapy can be provided to strengthen a weak ankle to prevent ankle instability.

If conservative management fails to relieve the patient's symptoms, surgical decompression of the entrapped nerve can be performed. The deep peroneal nerve is released from compressive forces in the entrapment site. This can be performed at the more proximal level at the extensor retinaculum or more distally at the level of the tarsal metatarsal site.

## References

- [1] Liu Z, Zou J, Zhao L. Anterior tarsal tunnel syndrome. *J Bone Joint Surg Br* 1991;73:470-3.
- [2] Kopell HP, Thompson WAL. Peripheral entrapment neuropathies of the lower extremity. *N Engl J Med* 1960;262:56-60.
- [3] Marinacci AA. *Applied electromyography*. Philadelphia: Lee & Febiger; 1968.
- [4] Marinacci AA. Neurological syndromes of the tarsal tunnels. *Bull LA Neurol Soc* 1968;33: 90-100.
- [5] Akyüz G, Yilmaz IT. Anterior tarsal tunnel syndrome. *Electromyogr Clin Neurophysiol* 2000;40:123-38.
- [6] Abdul-Latif MS, Clarke S. Anterior tarsal tunnel syndrome in the post partum period. *Int J Obstet Anesth* 2001;10(1):75-6.

- [7] Baumhauer JF. Entrapment of the deep peroneal nerve. *Foot Ankle Clin N Am* 1998;3(3): 427–37.
- [8] Sarrafian S. The anatomy of the foot and ankle. Philadelphia: J.B. Lippincott; 1983.
- [9] Adelman KA, Wilson G, Wolf JA. Anterior tarsal tunnel syndrome. *J Foot Surg* 1988;27(4): 299–302.
- [10] Gutmann L. Atypical deep peroneal neuropathy in presence of accessory deep peroneal nerve. *J Neurol Neurosurg Psychiatry* 1970;33:453–6.
- [11] Infante E, Kennedy WR. Anomalies branch of the peroneal nerve detected by electromyography. *Arch Neurol* 1970;22:162–5.
- [12] Lambert EH. The accessory deep peroneal nerve: a common variation in innervation of extensor digitorum brevis. *Neurology* 1969;19:1169–76.
- [13] Rubin M, Menche D, Pitman M. Entrapment of an accessory superficial peroneal sensory nerve. *Can J Neurol Sci* 1991;18:342–3.
- [14] Kanbe K, Kubota H, Shirakura K. Entrapment neuropathy of the deep peroneal nerve associated with the extensor hallucis brevis. *J Foot Ankle Surg* 1995;34(6):560–2.
- [15] Hirose CB, McGarvey WC. Anterior tarsal tunnel syndrome. *Foot Ankle Clin N Am* 2004;9: 255–69.
- [16] Schon LC, Baxter DE. Neuropathies of the foot and ankle in athletes. *Clin Sports Med* 1990; 9:489–509.
- [17] Kravette M. Peripheral nerve entrapment syndromes in the foot. *JAPA* 1971;61:457–72.
- [18] Borges L, Hallett M, Selkoe B, et al. The anterior tarsal tunnel syndrome. *J Neurosurg* 1981; 54:89–92.
- [19] Cangialosi CP, Schnall SJ. The biomechanical aspects of anterior tarsal tunnel syndrome. *J Am Podiatry Assoc* 1980;70:291–2.
- [20] Hirose CB, McGarvey WC. *Foot Ankle Clin N Am* 2004;9:255–69.
- [21] Gessini L, Jandolo B, Pietrangeli A. The anterior tarsal tunnel syndrome. *J Bone Joint Surg* 1984;66A:786–7.
- [22] McGlamry ED. Acquired neuropathies of the lower extremities. *Comprehensive textbook of foot surgery*, 2<sup>nd</sup> edition. Baltimore (MD): Williams and Williams; 1992. p. 1106–10.
- [23] Krause KH, Witt T, Ross A. The anterior tarsal tunnel syndrome. *J Neurol* 1977;217:67–74.