




Contents lists available at ScienceDirect

The Journal of Foot & Ankle Surgery

journal homepage: www.jfas.org



Tips, Quips, and Pearls

"Tips, Quips, and Pearls" is a special section in The Journal of Foot & Ankle Surgery which is devoted to the sharing of ideas to make the practice of foot and ankle surgery easier. We invite our readers to share ideas with us in the form of special tips regarding diagnostic or surgical procedures, new devices or modifications of devices for making a surgical procedure a little bit easier, or virtually any other "pearl" that the reader believes will assist the foot and ankle surgeon in providing better care. Please address your tips to: D. Scot Malay, DPM, MSCE, FACFAS, Editor, The Journal of Foot & Ankle Surgery, PO Box 590595, San Francisco, CA 94159-0595; E-mail: editorjfas@gmail.com

Double Calcaneal Osteotomy Using Single, Dual-Function Screw Fixation Technique

Lawrence A. DiDomenico, DPM, FACFAS¹, A. Anthony Haro III, DPM, FACFAS², Davina J. Cross, DPM³

¹ Section Chief, Department of Podiatry, Department of Surgery, St. Elizabeth Health Center, Youngstown; Private Practice, The Ankle and Foot Care Centers, Boardman, OH

² Private Practice, Ankle and Foot Surgical and Podiatry Clinic, West End, NC

³ Resident, Heritage Valley Health Systems, Beaver, PA

ARTICLE INFO

Keywords:
bone
calcaneus
lag screw
surgery

ABSTRACT

Historically, a variety of fixation techniques for calcaneal osteotomies have been used. The prevention of postoperative sequelae, including delayed or nonunion of the osteotomy sites and minimization of soft tissue damage, is always a primary consideration for foot and ankle surgeons. The present report describes a fixation technique for a double calcaneal osteotomy that entails use of a single screw that functions as both a positional tool, as well as a compressive fixation device. This technique provides compressive and positional qualities and decreases the amount of soft tissue disruption to the surgical site.

© 2011 by the American College of Foot and Ankle Surgeons. All rights reserved.

Calcaneal osteotomy procedures have been recognized as a treatment for flatfoot deformity and posterior tibial tendon dysfunction since the late 1800s (1). These procedures offer an advantage over arthrodesis and tendon transfer techniques, because they allow for maintenance of joint and muscle function while still correcting severe deformity in multiple planes (2). In the early 1970s, Koutsogiannis (3) detailed the use of a medial transposition calcaneal osteotomy, followed by the description by Evans (4) of an osteotomy in the distal calcaneus with insertion of a bone graft. When used together, they are known as a double calcaneal osteotomy. The double calcaneal osteotomy allows for lengthening of the lateral column of the foot, restoration of the anatomic position of the calcaneus under the talus, and preservation of function of the surrounding joints.

A variety of fixation techniques have been described for these procedures when used individually or combined. When used independently, the original fixation methods included placement of two Kirschner wires for one and impaction for the other (3, 4). More recently, DeYoe and Wood (5) recommended the use of staple or plate fixation across the graft site in the Evans osteotomy. Numerous fixation techniques have been reported for use in the double calcaneal osteotomy procedure. Frankel et al (6) described using Steinman pins for the calcaneal slide and simple impaction for the Evans

procedure. Multiple investigators have discussed using a 3.5-mm cortical screw across the Evans osteotomy site combined with two parallel 6.5-mm cancellous screws across the medial displacement calcaneal osteotomy site (7, 8). Other investigators have detailed the use of two percutaneous Kirschner wires (9). In addition, successful outcomes with the use of unilateral rail external fixation have been documented (10).

In our report, we present a fixation technique using a single screw construct. The procedure achieves lag fixation of the posterior capital fragment of the calcaneus associated with the calcaneal slide osteotomy and concurrently attains positional fixation of the anterior capital fragment and tricortical bone graft associated with the Evans calcaneal osteotomy.

Surgical Technique

The patient is placed supine on the operating table, with or without an ipsilateral hip bump, with the foot extending off the end of the operative table to provide access to the medial, lateral, and posterior calcaneus. The calcaneal slide osteotomy is completed, and the posterior capital fragment of the calcaneus is translated medially to reduce the calcaneal valgus and improve alignment of the rear foot in relation to the leg. To achieve temporary fixation, a guidewire from a large cannulated screw set is placed in the superior one half of the calcaneus, with orientation from proximal-inferior-central to distal-superior-lateral, crossing perpendicular to the osteotomy site. Care is taken to stop within the subcortical bone of the subtalar joint (Figure 1).

Financial Disclosure: None reported.

Conflict of Interest: None reported.

Address correspondence to: Lawrence A. DiDomenico, DPM, FACFAS, Private Practice, The Ankle and Foot Care Centers, 8175 Market Street, Boardman, OH 44512.

E-mail address: ld5353@aol.com (L.A. DiDomenico).

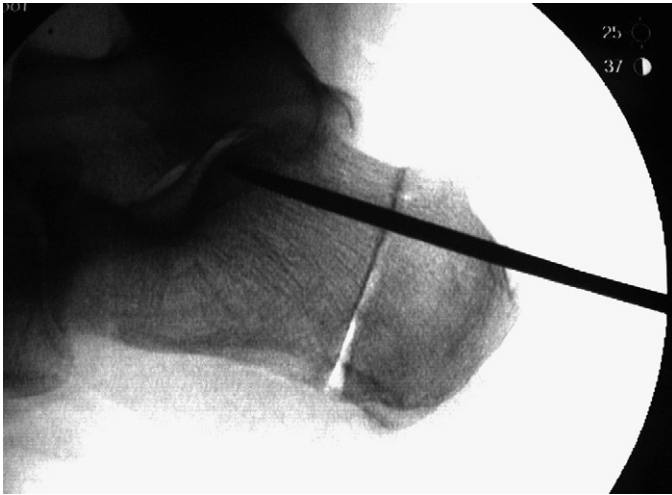

Fig. 1. Guidewire placed in superior one half of calcaneus to achieve temporary fixation.

The second guidewire is then placed in the inferior one half of the calcaneus, oriented from proximal-inferior-central to distal-superior-lateral, crossing slightly oblique to the posterior capital fragment and extending into the anterior process of the calcaneus. The position is checked with fluoroscopy. The wire driver is placed on reverse, and the second (inferior) guidewire is repositioned such that the tip of the wire is approximately 3.0 cm proximal to the calcaneal cuboid joint. Attention is then directed to the lateral rear foot, where an Evans calcaneal osteotomy is completed approximately 1.5 cm proximal to the calcaneal cuboid joint and just distal to the previously positioned inferior calcaneal guidewire. The anterior capital fragment of the calcaneus is distracted to reduce forefoot abduction and better align the forefoot and midfoot with the rear foot. An appropriate custom-size trapezoidal wedge composed of a tricortical cancellous bone (allogeneic or autogenous) graft is oriented with the base, laterally and medially. This is then sculpted and tamped into the Evans osteotomy. According to patient size and surgeon preference, the selection of the size of the cancellous screw is determined for the most proximal screw. The proximal (superior), partially short-threaded cannulated screw is placed over the first guidewire and lagged across the translated posterior capital fragment of the

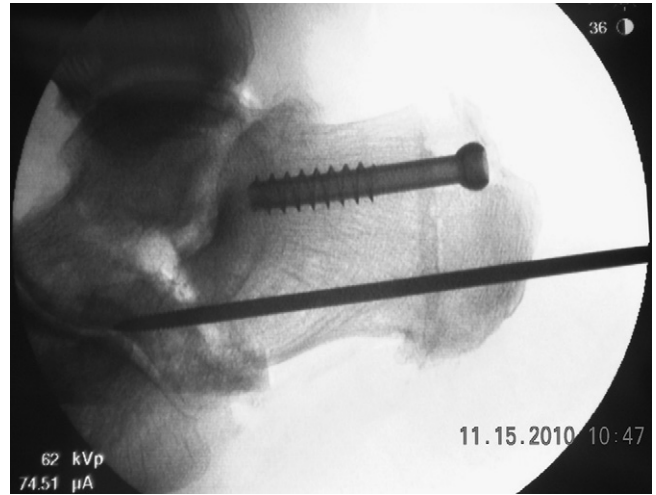


Fig. 3. Inferior calcaneal cannulated guidewire advanced across osteotomy site and bone graft and into anterior process of calcaneus into subchondral bone of distal aspect of calcaneus.

calcaneus, providing interfragmentary compression (**Figure 2**). The inferior calcaneal cannulated guidewire is advanced across the osteotomy site and bone graft and into the anterior process of the calcaneus into the subchondral bone of the distal aspect of the calcaneus (**Figure 3**). Intraoperative fluoroscopy is used to obtain oblique, lateral, anteroposterior, and calcaneal axial scans to verify correct positioning of the guidewire (**Figure 4**).

A partially long-threaded cannulated screw is inserted over the guidewire and driven across both calcaneal osteotomies and the bone graft. The inferior dual lag-positional screw is placed such that the threads are distal to the proximal slide osteotomy, thus providing interfragmentary compression, and concomitantly engaging the bone proximal to the Evans osteotomy, the bone graft, and the anterior process of the calcaneus (**Figure 5**). This partially long-threaded dual function screw provides excellent compression across the posterior capital fragment and acts as a positional screw, maintaining the length of the lateral column and not providing compression across the interpositional graft (**Figure 6**).

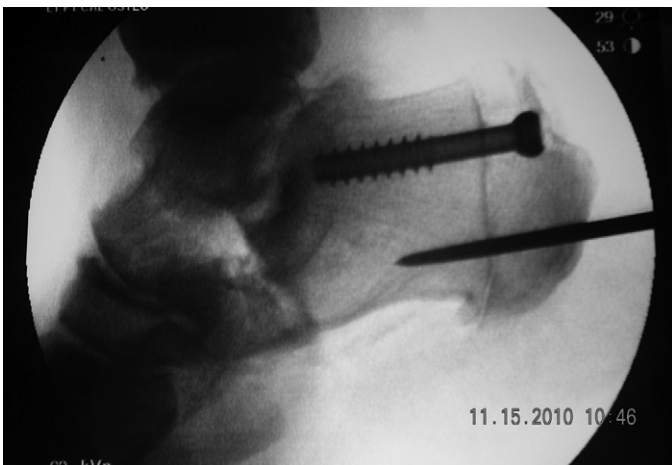

Fig. 2. Proximal (superior), partially short-threaded cannulated screw placed over first guidewire and lagged across translated posterior capital fragment of calcaneus to provide interfragmentary compression.

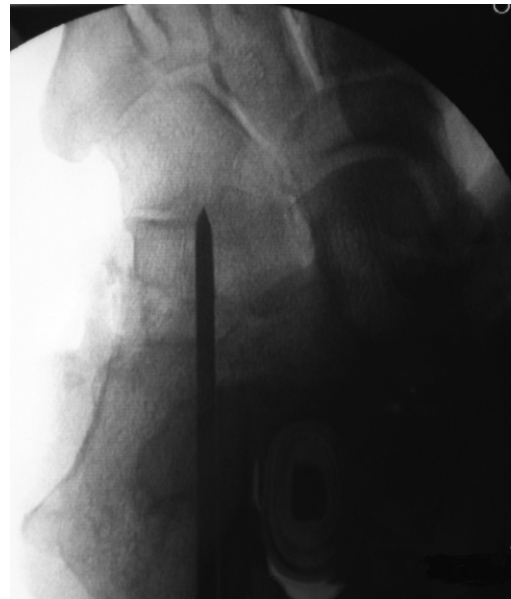

Fig. 4. Intraoperative fluoroscopy verifying correct positioning of guidewires.

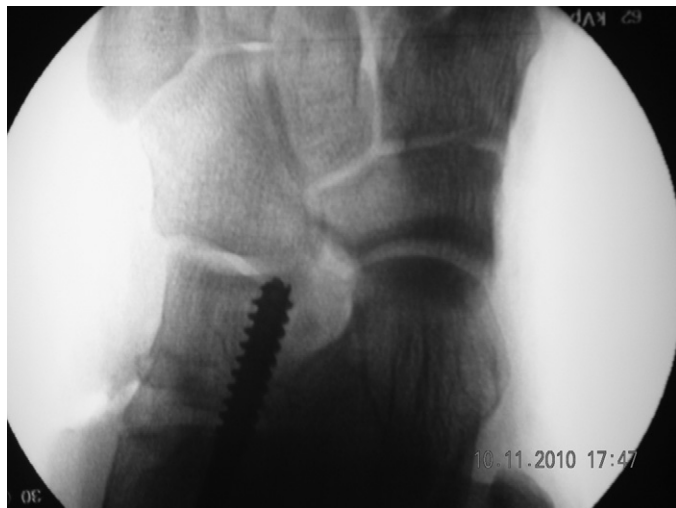

Fig. 5. Inferior dual lag-positional screw placed so that threads are distal to proximal slide osteotomy.

Discussion

A variety of fixation techniques have been reported for the double calcaneal osteotomy (1, 2, 8, 9, 11). However, revision is often required because of pain caused by bony nonunion (12). We have illustrated a technique using single-screw fixation that provides positional and compressive qualities about the osteotomy sites. This technique has specific advantages compared with other fixation methods, including increased lag effect across the posterior capital fragment of the calcaneus and positioning effect across the bone graft and anterior capital fragment of the calcaneus. Furthermore, the position of the screw across the graft site maintains its position by preventing subsidence, extraction, and dorsal migration. In conclusion, this method delivers compression across the medial calcaneal displacement osteotomy while acting as a buttress across the Evans distraction osteotomy. A paramount advantage of this fixation technique is that it is essentially intramedullary and eliminates the need for additional soft tissue dissection, decreasing the potential for wound and vascular injury to the local site. Technically, this procedure also eliminates the need for the more expensive use of plate fixation, thereby decreasing the probability of the need to remove painful

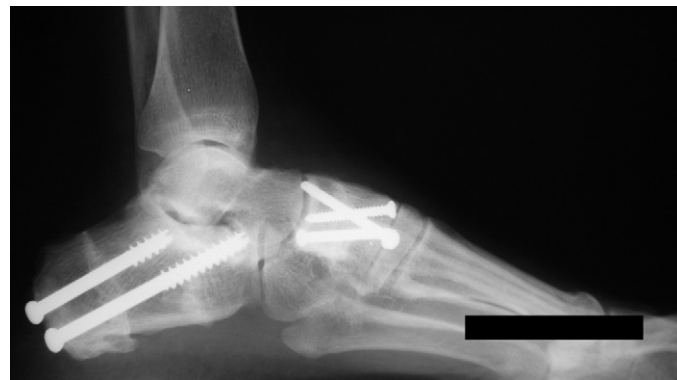

Fig. 6. Follow up radiograph showing long-threaded dual function screw providing excellent compression across posterior capital fragment and acting as positional screw.

hardware, and might allow for an improved surgical outcome in cases of double calcaneal osteotomy.

References

1. Soomekh DJ, Baravarian B. Pediatric and adult flatfoot reconstruction: subtalar arthroereisis versus realignment osteotomy surgical options. *Clin Podiatr Med Surg* 23:695–708, 2006.
2. Trnka HJ, Easley ME, Myerson MS. The role of calcaneal osteotomies for correction of adult flatfoot. *Clin Orthop Rel Res* 365:50–64, 1999.
3. Koutsogiannis E. Treatment of mobile flat foot by displacement osteotomy of the calcaneus. *J Bone Joint Surg Br* 53B:96–100, 1971.
4. Evans D. Calcaneo-valgus deformity. *J Bone Joint Surg Br* 57B:270–278, 1975.
5. DeYoe BE, Wood J. The Evans calcaneal osteotomy. *Clin Podiatr Med Surg* 22:265–276, 2005.
6. Frankel JP, Turf RM, Kuzmicki LM. Double calcaneal osteotomy in the treatment of posterior tibial tendon dysfunction. *J Foot Ankle Surg* 34:254–261, 1999.
7. Mosier-Laclair S, Pomeroy G, Manoli A. Operative treatment of the difficult stage 2 adult acquired flatfoot deformity. *Foot Ankle Clin* 6:95–119, 2001.
8. Pomeroy GC, Manoli A. A new operative approach for flatfoot secondary to posterior tibial tendon insufficiency: a preliminary report. *Foot Ankle Int* 18:206–212, 1997.
9. Basioni Y, El-Ganainy AR, El-Hawary A. Double calcaneal osteotomy and percutaneous tenoplasty for adequate arch restoration in adult flexible flatfoot. *Int Orthop* 35:47–51, 2011.
10. Penney NT, Viselli SJ, Holmes TR, Weiner RD. Double calcaneal osteotomy with a unilateral rail fixator for correction of pes planus. *Foot Ankle Spec* 2:194–199, 2009.
11. Hix J, Mendicino RW, Saltrick K, Catanzariti AR. Calcaneal osteotomies for the treatment of clubfoot. *Clin Podiatr Med Surg* 24:699–719, 2007.
12. Neufeld SK, Myerson MS. Complications of surgical treatments for adult flatfoot deformities. *Foot Ankle Clin* 6:179–191, 2001.