

# Subtalar Joint Arthrodesis for Elective and Posttraumatic Foot and Ankle Deformities



Lawrence A. DiDomenico, DPM<sup>a,b,c,\*</sup>,  
Danielle N. Butto, DPM, AACFAS<sup>d</sup>

## KEYWORDS

- Posttraumatic osteoarthritis subtalar joint • Subtalar joint arthrodesis
- Foot and ankle deformities

## KEY POINTS

- Identify the appropriate patient who suffers from posttraumatic subtalar joint osteoarthritis.
- Joint preparation is very important and most time should be spent preparing the joint for arthrodesis.
- Fixation construct needs to be done very well and effectively to provide a solid Arbeitsgemeinschaft für Osteosynthesefragen (AO) construct for good results.

Subtalar joint arthrodesis is a procedure used in posttraumatic arthritis, osteoarthritis, tarsal coalition management, posterior tibial tendon dysfunction, and inflammatory arthropathies.<sup>1,2</sup> It also can be used in deformity correction before or at the same time as total ankle arthroplasty and is incorporated in the tibial-talocalcaneal fusion. The goals of the procedure are to eliminate pain, improve function, restore stability, and realign the rearfoot.<sup>1</sup> The procedure has high patient satisfaction with low complications, while preserving motion in adjacent tarsal joints.<sup>1,3</sup> Union rates are reported from 84% to 100%.<sup>1,2,4</sup> Screw removal is reported between 13% and 22%<sup>4</sup> (**Fig. 1**).

This article discusses the use of the subtalar joint arthrodesis in both elective and posttraumatic foot and ankle deformities.

---

Disclosure Statement: There is no conflict with my consulting and business relationships as it pertains to this article.

<sup>a</sup> Northside Hospital, Youngstown, OH, USA; <sup>b</sup> Ankle and Foot Care Centers, KSU College of Podiatric Medicine, 8175 Market Street, Youngstown, OH 44512, USA; <sup>c</sup> St. Elizabeth Hospital, Youngstown, OH, USA; <sup>d</sup> St. Francis Hospital and Medical Center, Hartford, CT, USA

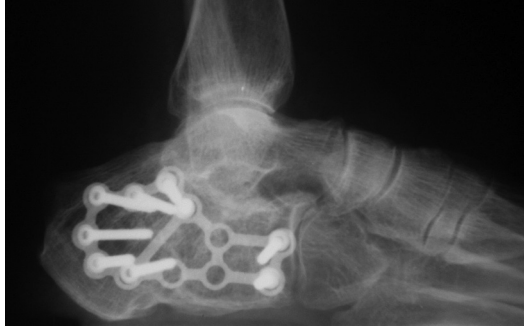\* Corresponding author. 8175 Market Street, Youngstown, OH 44512.

E-mail address: [LD5353@aol.com](mailto:LD5353@aol.com)

Clin Podiatr Med Surg 34 (2017) 327–338  
<http://dx.doi.org/10.1016/j.cpm.2017.02.004>

[podiatric.theclinics.com](http://podiatric.theclinics.com)

0891-8422/17/© 2017 Elsevier Inc. All rights reserved.



**Fig. 1.** A lateral radiograph projection demonstrating posttraumatic subtalar joint arthritis secondary to an unsuccessful open reduction internal fixation of a calcaneal fracture. Note the decrease in the calcaneal inclination angle, thus the talus sits more parallel to the ground instead of in a declination along and parallel to the first metatarsal. This change of the talar position also causes changes at the tibial talar joint where abutment of the talus occurs on dorsiflexion of the ankle. This impacts the ankle joint and will cause a limitation in range of motion at the ankle joint secondary to the position of the talus relative to the calcaneus.

## ANATOMY AND BIOMECHANICS

The subtalar joint is composed of the dorsal surface of the calcaneus and the plantar surface of the talus. There are 3 facets on each surface: anterior, middle, and posterior. The posterior facet of the calcaneus is the largest of the 3.<sup>5</sup> The sinus tarsi is located laterally as the end point of the sulcus tali and sulcus calcanei. The sulcus tali and calcanei form the sulcus tali in which the interosseus talocalcaneal ligament lies. The bifurcate and cervical ligaments along with the inferior extensor retinaculum insert on the sinus tarsi.<sup>3,6</sup>

The subtalar joint has both an extraosseous and intraosseous blood supply. The extraosseous blood supply to the subtalar joint comes from the posterior tibial artery, the anterior tibial artery, and the peroneal artery. The posterior tibial artery gives branches that anastomose with branches from the anterior tibial artery and the peroneal artery. The posterior tibial artery also gives off a branch known as the artery of the tarsal canal. The artery of the tarsal canal gives off a large branch to the talar body and smaller branches to the calcaneus. Additionally, it anastomoses with the artery of the sinus tarsi. The intraosseous blood supply centers around the talus. The talar head is supplied by the dorsalis pedis and the artery of the sinus tarsi. The main bloody supply to the body of the talus is from the anastomoses between the artery of the tarsal canal and branches of the dorsalis pedis. The body receives additional blood supply from the deltoid branch of the artery of the tarsal canal. The calcaneus and navicular have a rich vascular connection with the talus through intraosseous ligaments and the joint capsule.<sup>5</sup>

The subtalar joint is responsible for the conversion of rotatory forces of the lower extremity and dictates the movement of the midtarsal joint. The subtalar joint moves as a single unit around a single joint axis. The joint axis is oriented 42° from the horizontal plane and 16° from the sagittal plane oriented obliquely posterior-plantar-lateral to anterior-dorsal-medial. The joint exhibits triplanar motion.<sup>5</sup> Movement in the frontal plane occurs along the longitudinal/sagittal axis producing inversion and eversion. A 2:1 ratio of supination to pronation is considered “normal.” Movement in the transverse plane occurs along the vertical component of the axis. This movement is

referred to as abduction and adduction. Movement in the sagittal plane occurs along the frontal component of the axis, producing dorsiflexion and plantarflexion. The motion in the 3 planes occurs simultaneously, producing pronation or supination. Pronation consists of eversion, abduction, and dorsiflexion. Supination consists of inversion, adduction, and plantarflexion.<sup>5</sup>

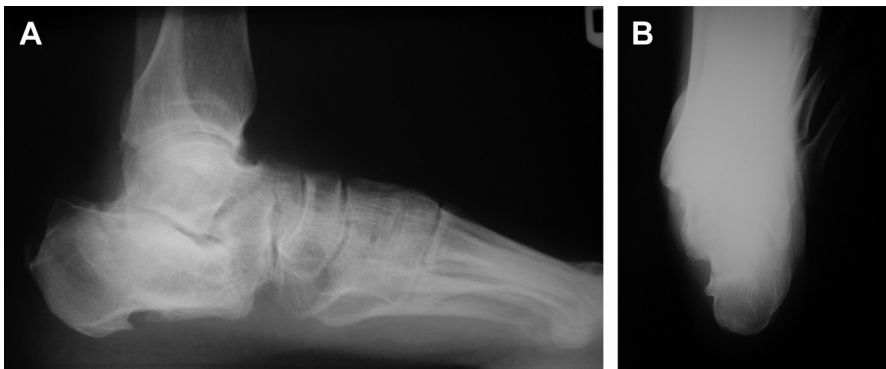
## **PATHOLOGY**

### ***Posttraumatic Arthritis***

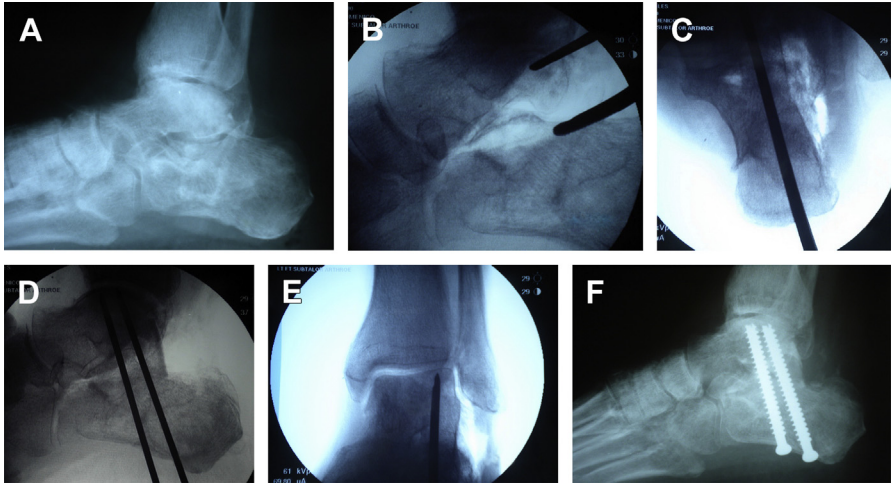
A well-known complication status post calcaneal fracture is subtalar joint arthritis. When the fracture is not primarily fixated, deformities, including an incongruous subtalar joint, decreased calcaneal height, lateral calcaneal wall widening, calcaneal-fibular abutment, peroneal tendon impingement, and hindfoot varus/valgus can ensue. The subtalar joint arthrodesis can be used to realign the rearfoot and decrease these postoperative complications while eliminating pain. In cases of decreased calcaneal height, an osteotomy or bone graft will have to be used to restore the height. One method is subtalar distraction bone block fusion. The talar and calcaneal joint surfaces are prepared for fusion. A lamina spreader is used to distract the subtalar joint to the appropriate height and also the surgeon needs to be sure the frontal plane is in neutral to slight valgus. A tricortical bone graft is then inserted. Two fully threaded large cancellous screws are then placed through the graft and across the joint<sup>7</sup> (Figs. 2 and 3).

### ***Osteoarthritis/Inflammatory Arthritis***

When arthritis, either osteo or inflammatory, is present in the subtalar joint that is painful and limits hindfoot function, a subtalar joint arthrodesis is warranted when bracing fails. The arthrodesis can be performed isolated if degenerative changes are isolated or in combination with a talonavicular, calcaneal-cuboid, or other midfoot arthrodesis procedures when degenerative changes are more widespread. Aston and colleagues<sup>8</sup> in a cadaveric study simulated arthrodesis of the subtalar joint. They found that 26% of the motion in the talonavicular joint and 56% of the motion of the



**Fig. 2.** A lateral and calcaneal axial preoperative radiograph projections in a patient who suffered a calcaneal fracture. (A) Lateral radiograph: Note the decrease in the calcaneal inclination angle, the subsequent change in Meary angle, secondary changes at the tibial talar joint, posttraumatic osteoarthritis, and malalignment of the subtalar joint. (B) Calcaneal axial: Note the widening of the calcaneus secondary to a lateral wall expansion and mild varus deformity.



**Fig. 3.** (A) A lateral radiograph in a patient who suffers from posttraumatic osteoarthritis secondary to a calcaneal fracture. (B) A intraoperative view demonstrating a lamina spreader being used to expose the subtalar joint for preparation of a tricortical cancellous bone graft. The lamina spreader is also used for getting the heel out of varus and into a neutral position. (C) An intraoperative calcaneal axial view following exostectomy of the lateral wall of the calcaneus to prevent lateral impingement symptoms. The guide wires for 2 large fully threaded cancellous screws are inserted in preparation for the fixation. (D) An intraoperative lateral fluoroscopic view is used to assess the position of the tricortical cancellous bone graft and guide wires in preparation for 2 large fully threaded positional screws to be inserted. Please note the angular changes of the talus with the tricortical cancellous bone graft in place. (E) An intraoperative ankle anteroposterior fluoroscopic view that is used to be sure the guide pins and screws do not enter the ankle joint. (F) A postoperative lateral radiographic projection demonstrating changes in the talus position as well as good incorporation of a tricortical cancellous bone graft with 2 large fully threaded positional screws.

calcaneocuboid joint was retained. Additionally, 46% of the excursion of the posterior tibial tendon was retained.

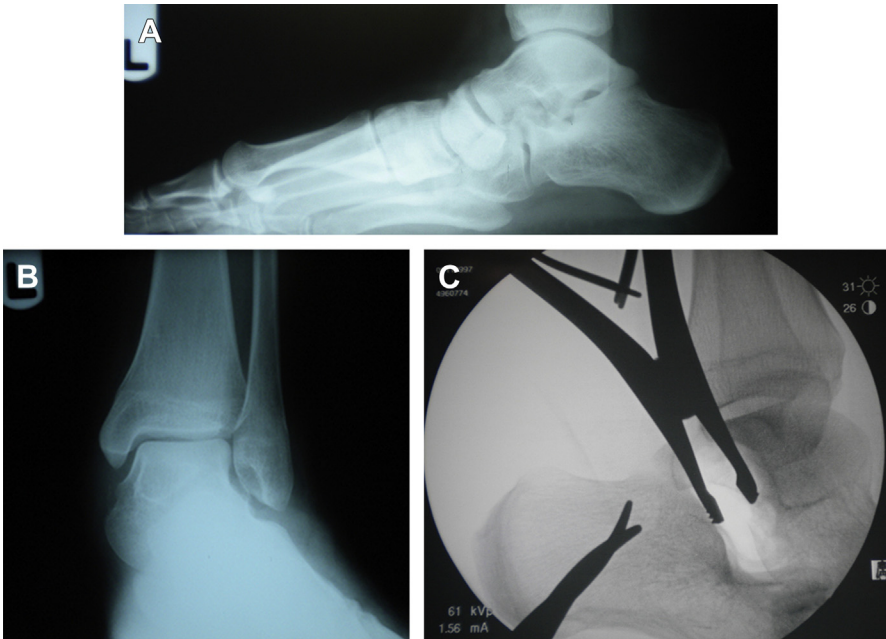
When the talonavicular joint is added to the arthrodesis, the motion of the remaining joints is limited to about  $2^\circ$  and the excursion of the posterior tibial tendon was limited to 25% of the preoperative value.<sup>8</sup>

### **Coalition**

A tarsal coalition is a congenital bridging between 2 or more tarsal bones. It is the most common cause of peroneal spastic flat foot. A subtalar joint coalition can occur between either the anterior, middle, or posterior facets, but the middle facet is the most common.<sup>9</sup> Subtalar joint coalitions commonly present between the ages of 12 and 16 but can also be seen in the adult population.<sup>10</sup> When conservative measures fail, surgical options include resection of the coalition or arthrodesis. Unfortunately, resection of the coalition seldom produces satisfactory results due to secondary degenerative changes that develop over time (Fig. 4).

### **Posterior Tibial Tendon Dysfunction**

Posterior tibial tendon dysfunction leads to pes planus deformity. The deformity is hallmarked by lateral column shortening, talar head uncovering, hyperpronation of the



**Fig. 4.** (A) This is a lateral radiograph of a patient who suffers from a painful flatfoot secondary to a middle facet talocalcaneal coalition. Note the changes of in the calcaneal pitch, the secondary changes of the navicular cuneiform joint, and elevation of the first metatarsal relative to the talus. (B) An ankle radiograph demonstrating a patient who suffers from a painful flatfoot deformity secondary to a middle facet talocalcaneal medial coalition. Note the exposure of the talar head medially and valgus deformity of the hindfoot. (C) An intraoperative lateral projection demonstrating a lamina spreader distracting the subtalar joint from a medial approach for a middle facet talocalcaneal coalition. The lamina spreader allows exposure to the subtalar joint and assists the surgeon in aligning the subtalar joint into a neutral position.

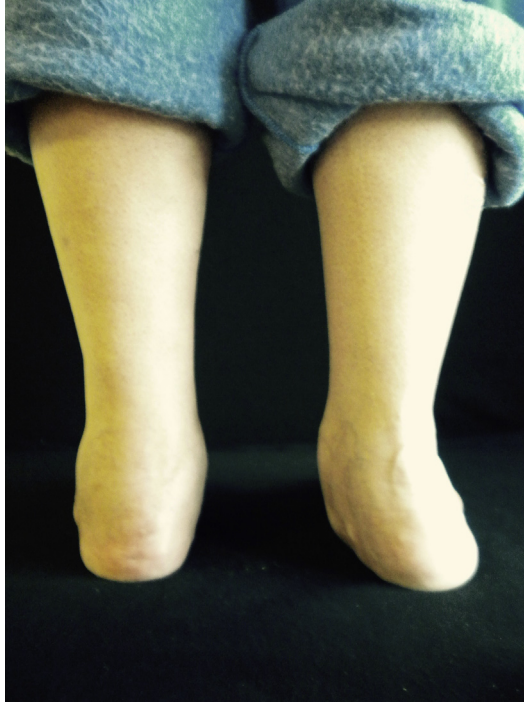subtalar joint, and valgus position of the calcaneus.<sup>11</sup> Fusion procedures are indicated in the stage III and stage IV pes planus deformity. In contrast to the triple arthrodesis, which has a high rate of progression of ankle joint arthritis, the isolated subtalar joint spares 26% of the talonavicular joint motion, 50% of the calcaneal-cuboid joint motion, and 46% of posterior tibial tendon excursion.<sup>3</sup> With proper positioning, the isolated subtalar joint arthrodesis resolves hindfoot valgus, eliminates hyperpronation, and restores the talo-first metatarsal angle (**Fig. 5**).

### **Ankle Pathology**

When osteoarthritis is present in both the subtalar joint and ankle, the surgeon may elect to perform a tibio-talocalcaneal joint fusion. This is typically fixated with an intramedullary nail or a femoral locking plate.<sup>12</sup> Additionally, the subtalar joint arthrodesis may be added to achieve proper rearfoot alignment before or in conjunction with total ankle arthroplasty. The hindfoot must be in rectus alignment to prevent failure of the implant.

### **PHYSICAL EXAMINATION**

The initial examination of any patient with suspected subtalar joint pathology should include vascular assessment and neurology examination, including assessing for



**Fig. 5.** A clinical view of a patient who suffers from posterior tibial tendon dysfunction. This patient has postoperative reconstruction consisting of the left subtalar joint arthrodesis left and preoperative right. Note the alignment difference once the subtalar joint is positioned appropriately.

positive Tinel sign. The subtalar joint range of motion should be assessed with the patient in the prone position. Normal subtalar joint range of motion includes 2:1 inversion to eversion. Rigid, limited range of motion may be indicative of a coalition. The position of the rearfoot should be assessed for valgus position of the heel. A valgus position may present in posterior tibial tendon dysfunction and in coalition. Peroneal spasm is a strong indication of coalition.

### **RADIOGRAPHIC EXAMINATION**

Anteroposterior, lateral, and oblique radiographs of the foot should be taken. Angles to examine include the calcaneal inclination angle, Meary angle, and Kite angle. With subtalar joint arthritis, one may encounter a decrease in calcaneal inclination while the Kite and Meary angles are increased. If the patient had previously sustained a calcaneal fracture the Gissane and Bohler angles should be examined. An increased Gissane angle and decreased Bohler angle suggest loss of height within the posterior facet. A lateral radiograph can be used to examine for a middle facet talocalcaneal coalition. A middle facet talocalcaneal coalition is suspected when a “halo-sign” is present inferior to the subtalar joint. In addition, specialty views can be taken to further examine the subtalar joint. An oblique lateral view can be taken to view the anterior joint. The medial aspect of the foot is placed on the film and the foot is inclined 45° to the film. The X-ray tube is centered 1 inch below and 1 inch anterior to the lateral



malleolus. A medial oblique axial can be taken to view the middle facet. The foot is dorsiflexed then inverted. The leg is medially rotated 60° and the foot is rested on a 30° wedge and the tube is directed axially 1 inch anterior and 1 inch below the lateral malleolus. The lateral oblique axial is used to visualize the posterior facet. The foot is dorsiflexed and everted. The limb is laterally rotated 60° and rested on a 30° wedge. The tube is directed axially and centered 1 inch below the medial malleolus (Ishewood). These specialized views can be tricky to take and some imaging centers may not offer these views. In these cases, advanced imaging, such as computed tomography (CT) and/or MRI may need to be ordered. A CT may be particularly advantageous in cases of posttraumatic arthritis. An MRI can be useful in the cases in which coalition is suspected.

### CONSERVATIVE TREATMENT

Conservative measures should be prescribed before surgery is considered. Oral nonsteroidal anti-inflammatories or topical compounding creams can be used for inflammatory control. Depending on the degree of deformity, orthotics may be useful to control hindfoot motion. If the deformity is more severe, bracing with an ankle-foot orthosis may be considered. Diagnostic injections into the sinus tarsi can be used. If the diagnostic block is successful, steroid can be added to the mixture to control intra-articular inflammation. When activities of daily living are affected by chronic subtalar joint pain, surgical intervention is warranted.

### SURGICAL MANAGEMENT

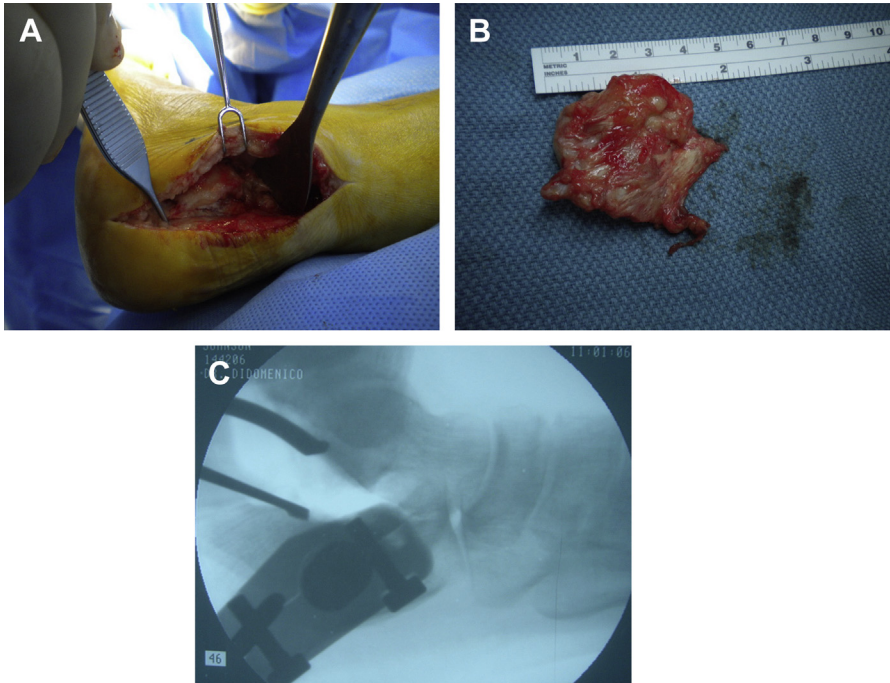
The patient is placed in the supine position with a hip bump. Choice of incision placement is based on the pathology. A commonly used incision is the lateral sinus tarsi incision. The incision extends from the distal fibula distally to the calcaneocuboid joint. A lateral extensile incision may be preferred if the patient has had previous calcaneal fracture fixation. Sharp and blunt is then used to penetrate down to the subcutaneous tissues. One must take care to visualize and retract the sural nerve if encountered. The deep fascia and extensor retinaculum are then identified. The subtalar joint should then be manipulated to identify the sinus tarsi and the lateral process of the talus. The deep fascia, extensor digitorum muscle belly, and periosteum are then dissected free to expose the sinus tarsi and the posterior facet. The sinus tarsi is then evacuated of its contents. Cartilage is resected from talar and calcaneal articular surfaces. When resecting cartilage along the medial aspect of the posterior facet, care should be taken to avoid the medial neurovascular structures.

If rearfoot position must be corrected, a bone wedge can be removed. The base of the resected wedge would be placed laterally for correction of rearfoot varus, while a medially based wedge would resect to correct rearfoot valgus.<sup>3</sup> Another option would be adding an autograft or allograft wedge to correct the hindfoot position.<sup>11</sup> The joint is then positioned in a neutral position while cupping the heel or dorsiflexing the foot. The guide pin is placed and subtalar joint position is assessed under fluoroscopy. Fixation techniques vary from single screw fixation to double. Additionally, the screws can be placed in a variety of orientations. A biomechanical study by Hungerer and colleagues<sup>13</sup> revealed that a delta configuration of the screws resulted in the greatest biomechanical stiffness with the lowest deflection of the arthrodesis. They found no significant difference between use of a 6.5-mm or 8.0-mm screw. The authors prefer to use large cannulated screws. A drain can be placed if deemed necessary.

Fusion can also be achieved arthroscopically. Lateral decubitus position is ideal for access via the anterolateral and posterolateral portals. A 2.7-mm scope is used to

visualize the subtalar joint. A shaver is used to remove all synovitis and burr, shavers, and curettes are used to remove all the cartilage.<sup>14</sup>

In cases of loss of height, incongruity, or severe malalignment in the subtalar joint, bone grafting may be necessary. A curvilinear incision parallel and posterior to the peroneal tendons is used.<sup>15</sup> A longitudinal, posterior incision may be used in a subtalar joint distraction to protect the soft tissues. This is especially useful when the anterior, medial, and/or lateral soft tissues have been violated from prior surgical attempts, local infection, or high-energy fractures.<sup>16</sup> A lamina spreader is placed in to the posterior subtalar joint and positioned to both distract the subtalar joint to the desired height as well as correct any frontal plane deformity if present. In more severe cases, a medial-based external fixator can be applied to help with distraction and allowing the subtalar joint to be placed in a neutral position. The resultant wedge is measured and a cortico-cancellous wedge is then cut and contoured to fit the void. Once placed and fixated, the remaining voids are tightly packed with crushed allograft, autograft, or bone substitutes depending on surgeon preference<sup>15</sup> (Fig. 6).



**Fig. 6.** (A) A posterior lateral approach for a patient who suffered a calcaneal fracture with significant height loss. The posterior lateral approach is used to protect the soft tissues when using a large tricortical cancellous bone graft for distraction of the subtalar joint. Because of the naturally occurring skin lines, the distraction causes less injury to the soft tissues posteriorly than it does laterally. (B) Image depicting an exostectomy of the lateral wall of the calcaneus to be used as an autogenous bone graft. Any remaining soft tissue attachments are removed and the bone is prepared in a bone mill to be morselized for later bone grafting. (C) An intraoperative lateral fluoroscopic view demonstrating a medial-based external fixator and lamina spreader used to address a varus deformity of the subtalar joint. The lamina spreader and external fixator maintain the position of the subtalar joint, as well assist with exposure while preparing the joint and inserting the tricortical cancellous bone graft.

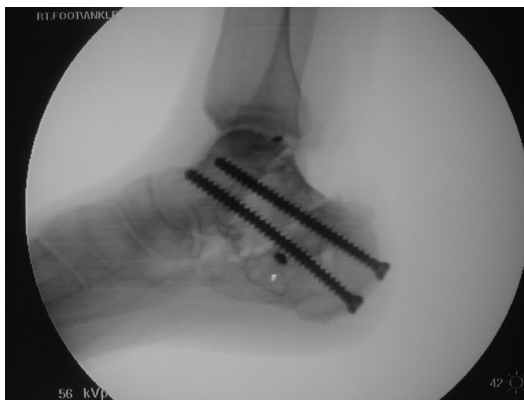

In cases of severe pes planus deformity, a subtalar joint arthrodesis may be combined with a talonavicular arthrodesis. In these cases, the surgeon may choose to use an isolated medial double approach rather than fusing the subtalar joint from the lateral approach. A curvilinear incision starts at the medial malleolus and comes out toward the plantar talonavicular joint. Care is taken to preserve the deltoid ligaments. Advantages to the procedure include direct visualization and easier manipulation to adequately reduce the displaced heel back underneath the talus with clear exposure to joint preparation for fusion.<sup>17</sup>

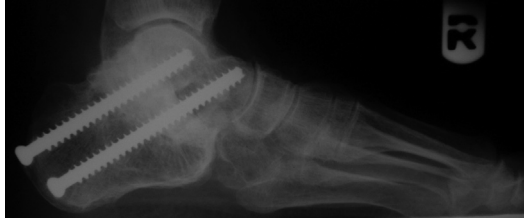No matter the approach or technique, hindfoot alignment should be checked intraoperatively with a calcaneal-axial view before final fixation is achieved. In some cases, a posterior calcaneal osteotomy may need to be combined with the subtalar joint fusion to reduce varus or valgus. Once adequate reduction of the deformity is achieved, fixation can be introduced. The types, size, and configuration of screws varies among surgeons. In a biomechanical evaluation of subtalar fusion, Hungerer and colleagues<sup>13</sup> assessed various screw configurations and types. They examined screws placed parallel, counter-parallel, and in a delta configuration. Additionally, they examined cannulated, partially threaded, and solid screws in both 6.5-mm and 8.0-mm screws. Their results found that the delta configuration resulted in the greatest biomechanical stiffness and lowest degree of deflection. Increasing the screw size from 6.5 to 8.0 mm resulted in no additional stability. Additionally, there was no statistical significance between solid and partially threaded cannulated screws (Figs. 7–9).

## FIXATION

Typically, 2 large cancellous screws are used in the subtalar joint when attempting an arthrodesis. The screws are either partially threaded or fully threaded based on the goal of the surgery. With an attempt to perform a subtalar joint arthrodesis, the authors advocate using 2 partially threaded large cancellous screws. The partially threaded cancellous screws will accomplish internal compression within the subtalar joint. In cases in which the goal is to perform a subtalar joint distraction arthrodesis, the authors advocate using 2 large cancellous fully threaded screws to maintain the distraction and position of the tricortical cancellous bone graft as well as the position of the talus relative to the calcaneus. Additionally, the 2 large fully threaded positional screws



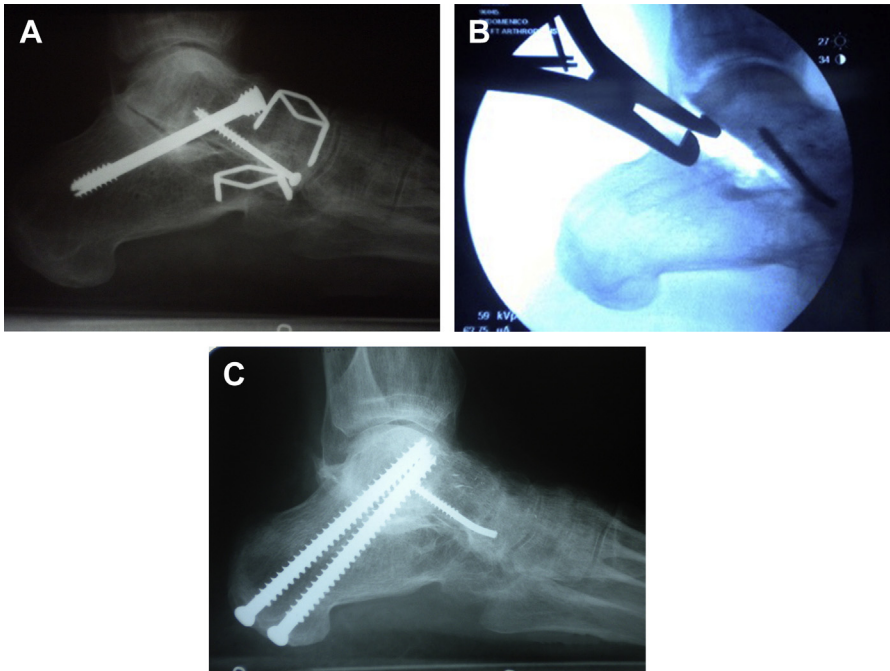
**Fig. 7.** An intraoperative lateral radiograph demonstrating a subtalar distraction arthrodesis realigning the hind foot and ankle. Two large fully threaded positional screws are used from inferior to superior.



**Fig. 8.** A postoperative lateral radiograph following incorporation of tricortical cancellous bone graft following a subtalar distraction arthrodesis for a patient who suffered from post-traumatic arthritis of the subtalar joint and ankle joint following a calcaneal fracture.

do not cause compression across the subtalar joint and the bone graft while maintaining the desired position.

The orientation of the fixation can be inserted from the talus to the calcaneus or from the calcaneus to the talus. The authors advocate inserting the fixation from the calcaneus to the talus. The advantage of inserting the fixation from the calcaneus to the talus is that the bone in the talus is much more dense and compact than in the calcaneus, and therefore better fixation can be achieved. Another advantage is the surgeon can avoid the possible injury to the neuromuscular structures that run along the anterior talus. Last, inserting the fixation from the calcaneus to the talus allows for targeted



**Fig. 9.** (A) A patient who suffers from a painful nonunion of the subtalar joint following a triple arthrodesis. (B) An intraoperative lateral view exposing the subtalar joint in preparation for an arthrodesis. (C) A postoperative lateral view demonstrating a good bony union of the subtalar joint following revision surgery of the subtalar joint with bone graft.

areas of the talar dome as well as the talar head and neck. The authors advocate 2 large threaded cancellous screws to provide more stability and prevent rotation.

### POSTOPERATIVE PROTOCOL

The patient is placed in a below-knee plaster cast for 2 weeks and then transitioned to a below-knee fiberglass cast for an additional 4 to 6 weeks. Once trabeculation is noted, the patient is transitioned to a walking boot for an additional 2 to 4 weeks. They are then transitioned to regular shoe gear as tolerated.

### COMPLICATIONS

Hematoma, seroma, incision dehiscence, ulceration, and neuritis can occur postoperatively.

Soft tissue infection is managed with culture and sensitivity, antibiotics, local wound care, and surgical debridement if necessary.

As with any arthrodesis, nonunion, delayed union, and malunion are possible. Higher rates of nonunion are associated with arthrodesis following posttraumatic arthritis.<sup>17</sup> Good surgical technique and rigid fixation will help to decrease risk of nonunion. In cases of hypertrophic nonunion, the use of an external bone stimulator may be necessary. If an atrophic nonunion ensues, reoperation may be necessary.

Malalignment is a risk when correcting deformities. Typically, a varus alignment is not tolerated well and may require a posterior calcaneal osteotomy to correct. Valgus alignment may be treated with orthotics/bracing.

Painful retained hardware can be removed once a solid fusion is achieved at the subtalar joint.<sup>18</sup>

### DISCUSSION

Subtalar joint arthrodesis is a procedure that can be used to treat posttraumatic arthritis, osteoarthritis, a talocalcaneal, and pes planus. It also can be added to ankle procedures as deemed necessary. The goals of the procedure are to eliminate pain, improve function, restore stability, and realign the rearfoot. The procedure is known to have high patient satisfaction with low complications while preserving motion in adjacent tarsal joints.

### REFERENCES

1. Catanzariti A, Mendicino R, Saltrick K, et al. Subtalar joint arthrodesis. *J Am Podiatr Med Assoc* 2005;95(1):34–41.
2. Haskell A, Pfeiff C, Mann R. Subtalar joint arthrodesis using a single lag screw. *Foot Ankle Int* 2004;25(11):774–7.
3. Lopez R, Singh T, Banga S, et al. Subtalar joint arthrodesis. *Clin Podiatr Med Surg* 2012;29(1):67–75.
4. Diezi C, Favre P, Vienne P. Primary isolated subtalar arthrodesis: outcome after 2 to 5 years followup. *Foot Ankle Int* 2008;29(12):1195–202.
5. Rockar P. The subtalar joint: anatomy and joint motion. *J Orthop Sports Phys Ther* 1995;21(6):361–72.
6. Isherwood I. A radiological approach to the subtalar joint. *J Bone Jt Surg* 1961; 43B(3):566–74.
7. Carr J, Hansen S, Benirschke SK. Subtalar distraction bone block fusion for late complications of os calcis fractures. *Foot Ankle* 1998;9(2):81–6.

8. Astion D, Deland J, Otis J, et al. Motion of the hindfoot after simulated arthrodesis. *J Bone Jt Surg* 1997;79A(2):241–6.
9. Kulik S, Clanton T. Tarsal coalition. *Foot Ankle Int* 1996;17(5):286–96.
10. Schwartz J, Kihm C, Camasta C. Subtalar joint distraction arthrodesis to correct calcaneal valgus in pediatric patients with tarsal coalition: a case series. *J Foot Ankle Surg* 2015;54(6):1151–7.
11. Chou L, Halligan B. Treatment of severe, painful pes planovalgus deformity with hindfoot arthrodesis and wedge-shaped tricortical allograft. *Foot Ankle Int* 2007;28(5):569–74.
12. DiDomenico L, Wargo-Dorsey M. Tibiotalocalcaneal arthrodesis using a femoral locking plate. *J Foot Ankle Surg* 2012;51:128–32.
13. Hungerer S, Eberle S, Lochner S, et al. Biomechanical evaluation of subtalar fusion: the influence of screw configuration and placement. *J Foot Ankle Surg* 2013;52:177–83.
14. Glanzmann M, Sanhueza-Hernandez R. Arthroscopic subtalar arthrodesis for symptomatic osteoarthritis of the hindfoot: a prospective study of 41 cases. *Foot Ankle Int* 2007;28(1):2–7.
15. Pollard J, Schuberth J. Posterior bone block distraction arthrodesis of subtalar joint: a review of 22 cases. *J Foot Ankle Surg* 2008;47(3):191–8.
16. Hersh I, Fleming J. Considerations of a midline posterior approach to the ankle and subtalar joints [Chapter 18]. Podiatry Institute; 2010.
17. Chang T. Double hindfoot arthrodesis versus triple arthrodesis for difficult hind-foot valgus deformities [Chapter 20]. Podiatry Institute; 2014.
18. Bibbo C, Anderson R, Davis WH. Complications of midfoot and hindfoot arthrodesis. *Clin Orthopedics Relat Res* 2001;(391):45–58.